

# Hypertension

JOURNAL OF THE AMERICAN HEART ASSOCIATION



*Learn and Live*<sup>SM</sup>

## **Cerebrovascular Function in Pregnancy and Eclampsia**

Marilyn J. Cipolla

*Hypertension* 2007;50;14-24; originally published online Jun 4, 2007;

DOI: 10.1161/HYPERTENSIONAHA.106.079442

Hypertension is published by the American Heart Association, 7272 Greenville Avenue, Dallas, TX 75214

Copyright © 2007 American Heart Association. All rights reserved. Print ISSN: 0194-911X. Online ISSN: 1524-4563

The online version of this article, along with updated information and services, is located on the World Wide Web at:

<http://hyper.ahajournals.org/cgi/content/full/50/1/14>

Subscriptions: Information about subscribing to Hypertension is online at  
<http://hyper.ahajournals.org/subscriptions/>

Permissions: Permissions & Rights Desk, Lippincott Williams & Wilkins, a division of Wolters Kluwer Health, 351 West Camden Street, Baltimore, MD 21202-2436. Phone: 410-528-4050. Fax: 410-528-8550. E-mail:  
[journalpermissions@lww.com](mailto:journalpermissions@lww.com)

Reprints: Information about reprints can be found online at  
<http://www.lww.com/reprints>

# Cerebrovascular Function in Pregnancy and Eclampsia

Marilyn J. Cipolla

**H**ypertension is one of the most common medical complications of pregnancy that affects both fetal and maternal health and is often life threatening.<sup>1,2</sup> Multiple maternal organs are affected by hypertension in pregnancy, including the brain in the form of eclampsia.<sup>1-4</sup> Eclampsia is a leading cause of maternal death, with classic neurologic symptoms that include headaches, nausea, vomiting, cortical blindness, coma, and convulsions.<sup>5-9</sup> Although numerous organs are affected by hypertension in pregnancy, cerebrovascular involvement is the direct mechanism of death in  $\approx 40\%$  of patients.<sup>6,7</sup> The major cerebrovascular changes in eclampsia have been shown to be similar to those described for hypertensive encephalopathy, including loss of cerebral blood flow (CBF) autoregulation, hyperperfusion, and edema.<sup>8-12</sup> In support of this concept, clinical and neuroimaging findings during eclampsia are consistent with edema, which is thought to result from a rapid rise in blood pressure that causes forced dilatation of cerebral vessels, breakthrough of autoregulation, and blood-brain barrier (BBB) disruption.<sup>12-15</sup> In fact, the neurologic symptoms of eclampsia are often interpreted as a form of hypertensive encephalopathy.<sup>8,16-18</sup>

It is well known that pregnancy is associated with significant cardiovascular adaptation of both local and systemic circulations.<sup>2,19-22</sup> Although the vascular changes that occur during pregnancy have been the subject of intense study in many organs, the effect of pregnancy and hypertension during pregnancy on the cerebral circulation is just coming to be understood. This review focuses on structural and functional changes in the cerebral circulation during normal pregnancy and the postpartum state that may contribute to the development of eclampsia, including changes in CBF autoregulation and cerebrovascular resistance (CVR) that enhance BBB permeability and hydrostatic brain edema. In addition, how hypertension during pregnancy, being somewhere between acute and chronic hypertension, affects the cerebral circulation is discussed.

## Eclampsia as a Form of Posterior Reversible Encephalopathy Syndrome

Eclampsia is defined in the obstetric literature as the new onset of seizures in a woman with preeclampsia, whereas preeclampsia is defined as blood pressure  $>140/90$  mm Hg

with significant proteinuria.<sup>1</sup> Although it is seizure that defines eclampsia, some neurologic symptoms can precede the onset of seizure, such as persistent headaches, blurred vision, photophobia, and altered mental status.<sup>1,2,6</sup> There has been considerable debate as to whether the neurologic symptoms of eclampsia arise from "overautoregulation" that causes vaso-spasm and ischemia or from hyperperfusion that causes cerebral edema formation.<sup>23</sup> This uncertainty over the cause of eclampsia is likely because clinical findings of eclampsia have shown varying degrees of hemorrhage, cerebral edema, and vasculopathy.<sup>1,8,11</sup> However, the reversibility of clinical neurologic signs and neuroradiologic lesions within a few days or weeks postpartum in most cases argues against the existence of true cerebral ischemic necrosis. In fact, the clinical and neuroimaging findings are more consistent with edema.<sup>5,8,13-15</sup> For example, the neuroradiologic hallmarks of eclampsia are reversible abnormalities that appear on computed tomography and T<sub>2</sub>-weighted magnetic resonance and diffusion-weighted images with high apparent diffusion coefficient, all suggestive of edema.<sup>5,14,15,18,24-28</sup>

The primary explanation for the pathogenesis of neurologic symptoms and edema formation during eclampsia is that it represents a form of reversible posterior leukoencephalopathy syndrome<sup>29</sup> or posterior reversible encephalopathy syndrome (PRES).<sup>30</sup> This syndrome is a variant of hypertensive encephalopathy with diverse causes, including immunosuppressive therapy, systemic lupus erythematosus, acute glomerulonephritis, and pregnancy.<sup>31</sup> Both hypertensive encephalopathy and PRES can arise from an acute elevation in blood pressure that overcomes the myogenic vasoconstriction of cerebral arteries and arterioles causing loss of autoregulatory capacity, BBB disruption, and vasogenic edema.<sup>8,12-15</sup> The concept that eclampsia can cause PRES has arisen from numerous similarities in clinical presentation including comparable imaging findings on computed tomography and MRI,<sup>3,5,18,31-33</sup> the same neurologic symptoms (headache, vomiting, cortical blindness, and seizures),<sup>3,9,16,17</sup> and the prompt reversibility of symptoms after blood pressure has been restored.<sup>3,9</sup>

The difference between hypertensive encephalopathy and PRES is that PRES can develop without a significant elevation in blood pressure.<sup>31</sup> In fact, eclampsia can occur at blood pressures that are considerably lower than those reported for hypertensive encephalopathy (discussed below),<sup>31,34</sup> making

---

Received March 6, 2007; first decision March 20, 2007; revision accepted May 3, 2007.

From the Departments of Neurology, Obstetrics and Gynecology, and Pharmacology, University of Vermont College of Medicine, Burlington.

Correspondence to Marilyn J. Cipolla, Department of Neurology, University of Vermont, 89 Beaumont Ave, Given C454, Burlington, VT 05405.  
E-mail Marilyn.Cipolla@uvm.edu

(*Hypertension*. 2007;50:14-24.)

© 2007 American Heart Association, Inc.

*Hypertension* is available at <http://www.hypertensionaha.org>

DOI: 10.1161/HYPERTENSIONAHA.106.079442

the designation of PRES more appropriate. The occurrence of cerebral edema and neurologic complications at normal blood pressures during eclampsia suggests that autoregulatory breakthrough is not necessary but may be more related to diminished autoregulatory capacity or enhanced BBB permeability (because of either normal pregnancy or endothelial damage, discussed below) or a combination of both. In any case, the cerebral circulation is the primary effector of these symptoms and is central to the pathogenesis of eclampsia. Understanding how pregnancy and the postpartum state affect the structure and function of this unique vascular bed may provide important clues as to how eclampsia develops and to potential treatments of this devastating condition.

### Brain Edema in Pregnancy and Eclampsia

Brain edema can be characterized as cytotoxic or vasogenic depending on whether or not the BBB is disrupted.<sup>34</sup> Cytotoxic edema occurs when brain cells, most notably astrocytes, swell at the expense of the extracellular space while the BBB remains intact. Vasogenic edema occurs when cerebrovascular permeability is increased because of BBB disruption that allows an influx of plasma constituents into the brain and expansion of the extracellular space. Because the increase in brain water associated with vasogenic edema occurs within the closed space of the skull, edema causes progressive brain compression and the classic neurologic symptoms of headache, nausea, vomiting, cortical blindness, and convulsions.<sup>10,35</sup> The edematous brain can also displace brain structures and reduce perfusion, ultimately leading to infarction or herniation, common causes of death in eclampsia.<sup>5,36,37</sup> Although hypertensive encephalopathy-related brain edema occurs in several conditions including acute hypertension and cyclosporin A immunosuppressive therapy, it is most often reported in obstetrics cases.<sup>38,39</sup>

The formation of vasogenic brain edema in hypertensive encephalopathy is caused by increased BBB permeability and/or enhanced water flux into the brain because of pathologically increased blood hydrostatic pressure.<sup>39–42</sup> The cerebral endothelium that forms the BBB is unique in that in the intact brain, there is very low hydraulic conductivity and essentially no ionic or solute flux.<sup>43,44</sup> This unique configuration makes the effect of hydrostatic pressure on capillary filtration minimal and is a protective influence against vasogenic brain edema. However, under conditions in which there is diminished autoregulation, an acute rise in blood pressure can severely increase hydrostatic pressure on the microcirculation, causing endothelial cell damage, increased BBB permeability, and vasogenic edema.<sup>41</sup> This type of vasogenic edema is termed “hydrostatic brain edema” and is the primary explanation underlying the neurologic complications of hypertensive encephalopathy and eclampsia.<sup>40–42</sup>

The term “hydrostatic brain edema” was introduced by Ishii et al<sup>40</sup> in 1983 and results from an unfavorable hydrostatic pressure gradient between the cerebral blood vessels and brain tissue. Numerous studies in brain have shown that hydrostatic pressure alone is capable of causing BBB opening and edema formation.<sup>41,42,45,46</sup> In fact, the hydrostatic pressure gradient seems to be the major factor in determining both the degree of the initial insult and the subsequent deterioration

after the hypertensive event.<sup>42,45,46</sup> Similarly, it is the change in hydrostatic pressure during eclampsia, when autoregulation is diminished, that likely contributes to vasogenic edema and the neurologic complications associated with this condition.<sup>42</sup>

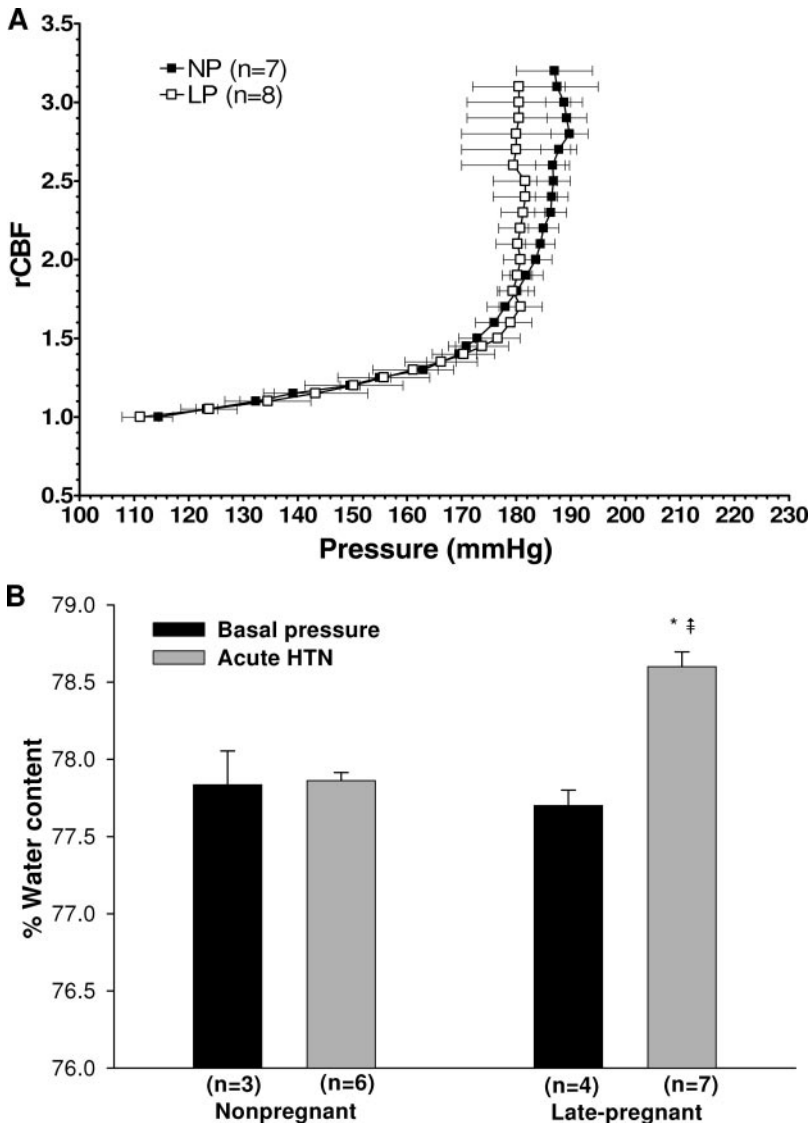
Our own study using a model of hypertensive encephalopathy in nonpregnant and late-pregnant rats found that whereas pregnancy did not affect the pressure at which autoregulatory breakthrough occurred, only late-gestation animals developed significant edema formation in response to autoregulatory breakthrough (Figure 1).<sup>47</sup> These results suggest that pregnancy alone predisposes the brain to the neurologic complications of eclampsia by promoting hydrostatic brain edema when blood pressure is acutely elevated. It should be noted that this study was conducted during normal rodent pregnancy and suggests that an acute elevation in pressure has a greater effect on brain edema during late gestation than the nonpregnant state. While interesting, the mechanism by which pregnancy enhances cerebral edema in response to acute hypertension is not clear. In addition, it is also not clear how a preexisting disease, such as preeclampsia, which has been shown to produce endothelial dysfunction and oxidative stress,<sup>1</sup> affects cerebral edema formation.

### Mechanisms of Brain Edema During Eclampsia

#### Cerebral Hemodynamics During Pregnancy and Eclampsia

Cerebrovascular resistance and CBF regulation are principally determined by vessel caliber, because blood flow is related to the fourth power of vessel radius.<sup>48</sup> Therefore, even small changes in lumen diameter have significant effects on CBF, and it is by this mechanism that CVR can change rapidly and dramatically to alter regional and global CBF.<sup>48,49</sup> In normotensive adults, CBF is maintained at  $\approx 50$  mL per 100 g of brain tissue per minute, provided cerebral perfusion pressure (CPP), defined as the difference between arterial pressure at the Circle of Willis, and intracranial pressure is in the range of  $\approx 60$  to 150 mm Hg (Figure 2).<sup>49,50</sup> Above and below this limit, autoregulation is lost and CBF becomes dependent on mean arterial pressure (MAP) in a linear fashion.<sup>48</sup> Significant brain tissue damage occurs when autoregulatory mechanisms are lost. For example, during acute hypertension at pressures above the autoregulatory limit, the myogenic constriction of vascular smooth muscle is overcome by the excessive intravascular pressure, and forced dilatation of cerebral vessels occurs.<sup>50–53</sup> Alternatively, autoregulation can be diminished or lost under pathologic conditions such as traumatic brain injury and stroke.<sup>54,55</sup> The loss of autoregulation decreases CVR, a result that produces hyperperfusion, BBB disruption, and vasogenic edema formation,<sup>5,51–53,56</sup> the underlying cause of the neurologic symptoms of hypertensive encephalopathy and eclampsia.<sup>5,56</sup>

One of the most pronounced cardiovascular adaptations that occurs during pregnancy is that maternal cardiac output and plasma volume increase by 40% to 50% by midgestation.<sup>22,57</sup> Total peripheral vascular resistance decreases significantly to accommodate the expansion in plasma volume,



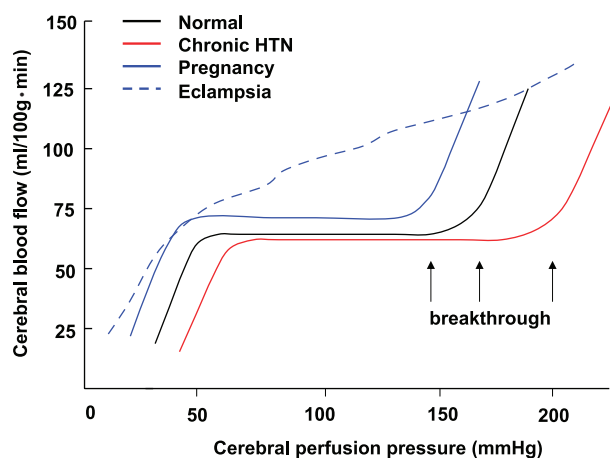
**Figure 1.** A, CBF autoregulatory curves from nonpregnant (NP) and late-pregnant (LP) anesthetized rats determined using laser Doppler and acute phenylephrine infusion. Notice that autoregulation was intact in both groups of animals from  $\approx 110$  to  $180$  mm Hg as demonstrated by little change in CBF with pressure. However, at pressures above  $\approx 180$  mm Hg, breakthrough occurred, substantially increasing CBF. There was no difference in the pressure of breakthrough between NP and LP animals. B, Cerebral edema formation in response to autoregulatory breakthrough in the same NP and LP rats shown in A. Notice that only the LP animals developed edema formation at this time point (10 minutes) after breakthrough. \* $P < 0.05$  vs NP; ‡  $P < 0.05$  vs LP basal pressure (partially published in *Hypertension*. 2007;49:334–340).<sup>47</sup>

and, therefore, blood pressure does not rise, but actually falls somewhat midgestation and rises again to normal at term.<sup>58</sup> Because of the large increase in cardiac output and plasma volume during normal pregnancy, how CBF and CVR are affected is of interest but is poorly understood. The most commonly used method to study cerebral hemodynamics is transcranial Doppler (TCD), because it is noninvasive and can measure changes in blood velocity. However, because changes in vessel caliber and intracranial pressure cannot be determined, CBF and other hemodynamic parameters such as CVR and CPP can only be inferred. Although most studies using TCD have found that middle cerebral artery velocity decreases as gestation progresses, other hemodynamic values reported are difficult to interpret from a hemodynamic standpoint. For example, Belfort et al<sup>60</sup> used the method of Aaslid et al<sup>59</sup> to calculate CPP and found that it increased from 44 to 66 mm Hg (50%) during the course of normal pregnancy from 12 to 40 weeks. This large increase in CPP is impossible, because intracranial pressure is only a few millimeters of mercury, and maternal blood pressure is not elevated during pregnancy (CPP=arterial pressure–intracranial pressure). In

fact, Kontos<sup>61</sup> severely criticized the use of TCD for measuring cerebral hemodynamics based on critical assumptions, such as no change in vessel caliber, that may not be accurate and may have important influences on outcome.

Velocity-encoded MRI can measure vessel diameter and has been used by Zeeman et al<sup>62</sup> to measure changes in CBF longitudinally during normal pregnancy. These authors found that CBF decreased 20% by late gestation in the large middle cerebral artery and presumed that downstream dilation of resistance vessels caused this change to maintain a steady hemodynamic state. Other studies using TCD have also found decreased CBF velocity over the course of gestation, with variable interpretations depending on whether downstream resistance was considered.<sup>60,63–65</sup>

TCD has also been used to study changes in cerebral hemodynamics during preeclampsia and eclampsia. During preeclampsia, when arterial pressure is significantly elevated, CPP has been found to be considerably higher than normal and, in some cases, cerebral resistance increased to limit perfusion,<sup>66–68</sup> suggesting that autoregulation is intact. Cerebral perfusion pressure was significantly higher in the pa-



**Figure 2.** CBF autoregulatory curves (hypothetical) under various conditions. The solid black line represents normal CBF as a function of CPP. Between  $\approx 60$  and 150 mm Hg, CBF remains relatively constant, whereas above and below these limits, autoregulation is lost and CBF changes linearly with pressure. The solid red lines represents chronic hypertension (chronic HTN) in which the autoregulatory curve is shifted to the higher pressures, likely because of medial hypertrophy and vascular remodeling of the cerebral arteries and arterioles. The solid blue line represents a potential shift in the autoregulatory curve during normal pregnancy. This has been hypothesized to explain why some women develop eclampsia at normal blood pressures; however, our experimental data do not support this shift (see Figure 1). The arrows point to pressures at which breakthroughs occur, demonstrating a large, steep increase in CBF. The dashed blue line demonstrates loss of autoregulation in which CBF changes linearly with pressure and is thought to occur during eclampsia.

tients with severe preeclampsia. Because women with severe preeclampsia are more prone to neurologic complications including eclampsia, these authors argued that elevated perfusion pressure can lead to autoregulatory breakthrough and overperfusion injury. Although most studies on severe preeclampsia have found that elevated CPP was associated with increased resistance, other studies have found that preeclampsia and eclampsia were associated with decreased resistance and hyperperfusion.<sup>12,69</sup> For example, one study comparing 6 patients with severe preeclampsia to 3 with eclampsia found that cerebral perfusion pressure was higher and CVR was decreased to a greater extent in the patients with eclampsia.<sup>12</sup> Decreased CVR during preeclampsia and eclampsia was further demonstrated in one study of 66 patients with hypertensive disorders (chronic, preeclampsia, and eclampsia) that found that hyperperfusion took place most significantly in patients with preeclampsia and eclampsia, but at MAPs that were considerably lower than normal values associated with the breakthrough of autoregulation.<sup>8</sup> An increase in CBF during preeclampsia was confirmed using  $T_2$ -weighted MRI.<sup>69</sup>

The importance of understanding cerebral hemodynamics during preeclampsia and eclampsia is that changes in these parameters can have a significant impact on BBB permeability and edema formation. In fact, the relationship between cerebral hemodynamics and BBB permeability has been extensively studied.<sup>70–74</sup> Numerous studies have found a positive correlation between increased brain blood flow and BBB permeability. For example, when CBF was compared in

areas with and without albumin extravasation in the same brain, the leaky regions were shown to have the highest blood flow, indicating loss of autoregulation and decreased CVR.<sup>24,74–77</sup> It is likely that decreased CVR and hyperperfusion found during eclampsia predisposes the brain to vasogenic edema by creating an unfavorable hydrostatic pressure gradient when pressure is elevated, regardless of the cause or degree of hypertension. In addition, preexisting disease, such as preeclampsia, which is known to affect endothelial cell function in the periphery, may further promote edema if the BBB is similarly affected. It is currently unknown how preeclampsia affects the cerebral endothelium.

### Autoregulation During Pregnancy and Eclampsia

Impaired cerebral autoregulation is thought to be a major influence in the development of eclamptic encephalopathy, making the effect of pregnancy on CBF autoregulation of significant interest.<sup>4,14,31–33</sup> In addition, many women who develop eclampsia do so at pressures that are considerably lower than those reported for PRES or hypertensive encephalopathy,<sup>23,31,78–80</sup> suggesting that the autoregulatory curve is shifted to the lower range of pressures during pregnancy or that autoregulatory capacity is severely affected (Figure 2). A shift in the autoregulatory curve would promote breakthrough at considerably lower pressures and may explain the development of edema without a significant elevation in pressure in some eclamptic women. Our own studies using laser Doppler to measure CBF autoregulation during late pregnancy in anesthetized rats found that there was no difference in autoregulation or the pressure of breakthrough compared with nonpregnant animals (Figure 1).<sup>47</sup> Although studies using laser Doppler can provide information regarding autoregulation of CBF and the pressure of breakthrough, how pregnancy affects CVR and hydrostatic pressure when blood pressure is elevated can be better obtained by techniques that measure absolute changes in CBF, for example, microspheres.

An understanding of CBF autoregulation changes during normal pregnancy is important, because women who develop eclampsia exhibit a wide spectrum of signs and symptoms ranging from severe hypertension and proteinuria to mild or absent hypertension with no proteinuria.<sup>31,78–80</sup> In a study of 53 pregnancies complicated by eclampsia, only 7 women (13%) could be considered to have severe preeclampsia before seizure.<sup>78</sup> In addition, another study showed that hypertension was absent in 16% of subjects, and<sup>79</sup> a similar result was found in a study of eclampsia in the United Kingdom.<sup>80</sup> High blood pressure ( $>120$  mm Hg diastolic) was recorded in only 70 of 383 or 20% of subjects. In fact, 21% had normal blood pressure (ie,  $<140/90$  mm Hg). Importantly, of 201 women whose blood pressures were recorded within 60 minutes of their first seizure, the mean diastolic pressure was only 97 mm Hg.<sup>80</sup> The fact that some women with eclampsia do not have the clinical definition of hypertension has led to the suggestion that eclampsia is not always a progression from severe preeclamptic disease to seizure (eclampsia).<sup>81</sup> This concept is also important for understanding the underlying cause of the neurologic complications of the disease. It is possible that the change in blood pressure necessary to promote hyperperfusion and

hydrostatic brain edema is considerably lower in pregnancy, making an increase to normal pressures pathologic. Alternatively, the autoregulatory curve could be shifted to the lower range of pressure during pregnancy, possibly because of the lower blood pressures that occur over the course of gestation; however, our own studies in a rat model of pregnancy did not confirm this.<sup>47</sup> Importantly, pressure alone may not be the only causative factor. Endothelial dysfunction that is known to occur in preeclampsia likely affects the cerebral endothelium as well, although how the BBB is affected under these conditions is not known.

Several studies have attempted to measure CBF autoregulation during normal pregnancy, preeclampsia, and eclampsia.<sup>82–84</sup> One study in which TCD was used to measure changes in CBF velocity in response to increases in blood pressure induced by a postural change from the left lateral to the supine position found that preeclamptic women had a more pronounced decrease in mean flow velocity, suggesting a stronger autoregulatory response.<sup>82</sup> Measurement of dynamic CBF autoregulation, a noninvasive technique that uses physiological changes in MAP to assess autoregulation, was performed on patients with eclampsia and found a substantial disturbance in CBF autoregulation.<sup>83,84</sup> This finding is not surprising given the strict similarities in the pathologic findings of eclampsia with hypertensive encephalopathy or PRES, including loss of autoregulation, hyperperfusion, and BBB disruption.

### **Myogenic Activity and Endothelial Function During Normal Pregnancy and Postpartum**

Although clinical studies have provided valuable information regarding the nature of eclampsia, mechanistic studies are understandably difficult. We have used isolated and pressurized posterior cerebral arteries during normal pregnancy and the postpartum state to investigate how these gestational states affect the underlying cellular mechanisms of diameter regulation, including myogenic activity, endothelial vasodilator production, and smooth muscle reactivity.<sup>85</sup> We found that arteries from both late-pregnant and postpartum animals underwent forced dilatation at considerably lower pressures than arteries from nonpregnant animals, suggesting that the autoregulatory curve is shifted to the lower range of pressures. This interpretation should be taken with caution, because this finding reflects only 1 isolated artery when in fact CBF autoregulation is influenced by several factors including neuronal, endothelial, and metabolic components, in addition to myogenic.<sup>86</sup>

Pregnancy and the postpartum state also appear to affect endothelial vasodilator production and smooth muscle reactivity. Cerebral arteries from late-pregnant and postpartum animals constricted in a concentration-dependent manner to serotonin, whereas arteries from nonpregnant animals dilated.<sup>85</sup> Because the dilation was in the presence of both cyclooxygenase and NO inhibition, these results suggest that arteries from nonpregnant animals produce endothelium-dependent hyperpolarizing factor in response to serotonin that is not present in arteries during pregnancy or the postpartum state that are more dominated by NO. The significance of this change in vasodilator production by the cerebral endothelium

is unclear; however, it is possible that these changes contribute to hemodynamic alterations during pregnancy, similar to the periphery.

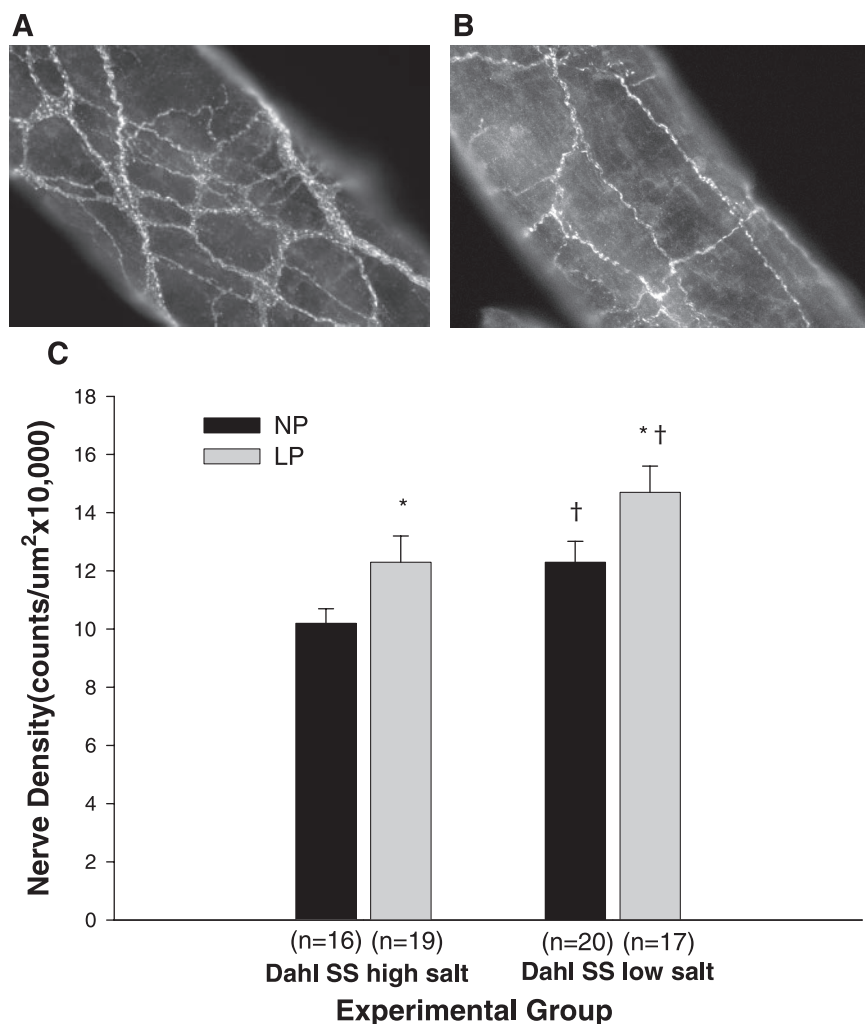
### **Perivascular Innervation**

Cerebral pial vessels are innervated extrinsically (ie, ganglia are peripheral in origin) with fibers that contain neurotransmitters from sympathetic, parasympathetic, and trigeminal systems.<sup>87</sup> Although these fibers are not thought to be important for control of basal CBF, sympathetic fibers are thought to limit hyperperfusion during acute elevations in pressure.<sup>76</sup> Interestingly, it appears that pregnancy has a trophic effect on perivascular innervation of cerebral pial vessels (Figure 3). Aukes et al<sup>88</sup> used a panneuronal stain to show that perivascular innervation of posterior cerebral arteries was increased during pregnancy in the Dahl salt-sensitive rat. Because specific neurotransmitters were not quantified, it is not clear what consequence, if any, this finding might have. Studies that investigate changes in specific neurotransmitters during pregnancy would be important to understanding the significance of these perivascular nerves. For example, trigeminal nerve fibers are nociceptive and may promote headache,<sup>89</sup> the most common symptom of eclampsia,<sup>90</sup> whereas sympathetic fibers have been shown to affect cerebral artery remodeling in response to chronic hypertension.<sup>91</sup>

### **Cerebrovascular Remodeling During Hypertension in Pregnancy**

Chronic hypertension is associated with cerebrovascular remodeling that is thought to be protective of the brain.<sup>92,93</sup> In particular, pressure-induced medial hypertrophy of both large and small cerebral arteries increases the wall:lumen ratio and serves to normalize circumferential wall stress that is elevated because of increased blood pressure.<sup>92–96</sup> Both hypertrophy and remodeling of large and small cerebral arteries attenuate the increased pressure in downstream microvessels, thereby protecting the BBB from disruption.<sup>97</sup> It should be noted that hypertension during pregnancy is a unique form of hypertension that is somewhere between acute and chronic. Therefore, the effect of hypertension during pregnancy on structural remodeling is largely unknown compared with what is known to occur during chronic hypertension.

Although medial hypertrophy of cerebral arteries is considered protective of the BBB, pregnancy appears to prevent this response to hypertension, potentially increasing the susceptibility to edema formation. Our own study examined how hypertension during pregnancy, induced by NO synthase inhibition, affected medial hypertrophy of posterior cerebral arteries.<sup>98</sup> NO synthase inhibition for just 7 days significantly raised arterial pressure in both nonpregnant and late-pregnant rats and caused significant medial hypertrophy in posterior cerebral arteries from nonpregnant animals. In contrast, cerebral arteries from late-pregnant animals lacked this response to hypertension and did not undergo medial hypertrophy. The observation that pregnancy prevents hypertensive remodeling and medial hypertrophy was further confirmed using another model of hypertension during pregnancy. A study that used Dahl salt-sensitive rats made hypertensive by feeding



**Figure 3.** Photomicrographs of perivascular nerves surrounding posterior cerebral arteries from nonpregnant (NP) and late-pregnant (LP) rats. There was considerably greater staining of protein gene product 9.5, a pan neuronal stain, in arteries from LP vs NP animals. A, Photomicrograph of a cerebral artery from a LP normotensive rat. B, Photomicrograph of a cerebral artery from a NP hypertensive rat. C, Graph of perivascular innervation of posterior cerebral arteries from NP and LP rats demonstrating a hypertrophic effect of pregnancy on perivascular innervation (used with permission from *Am J Physiol.* 2007;292:H1071–H1076).<sup>88</sup>

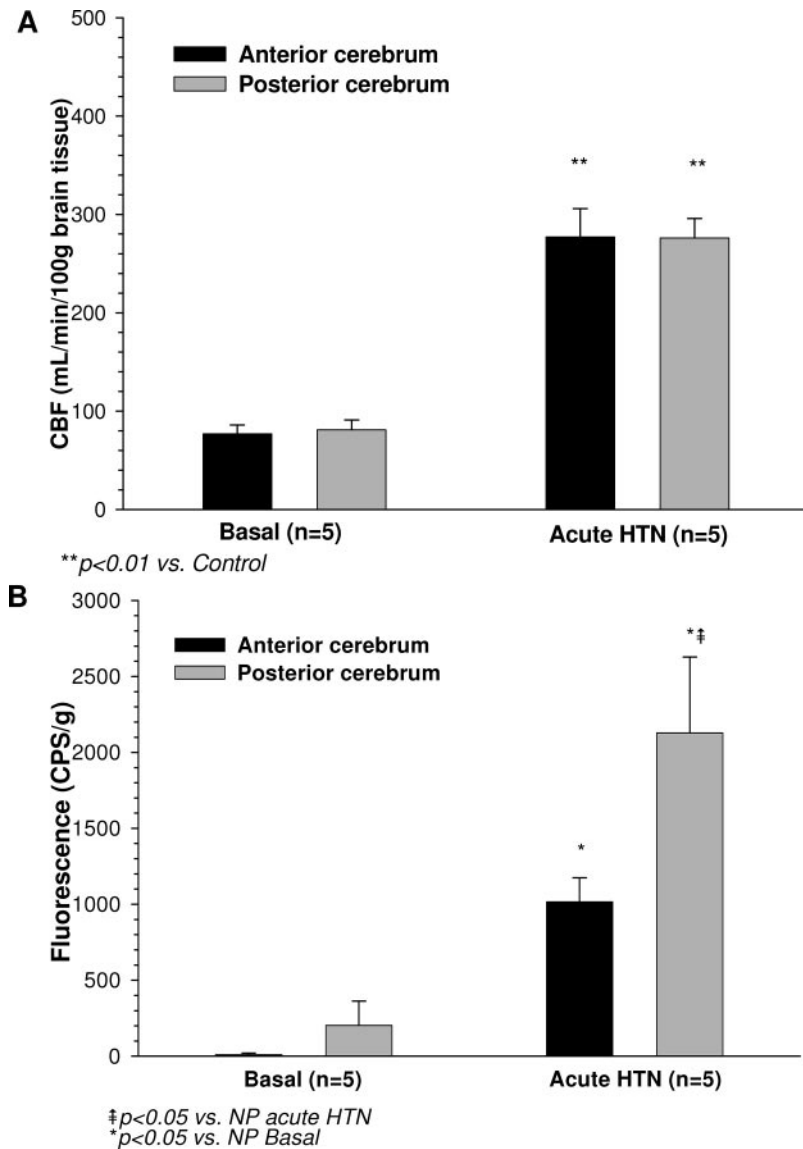
a high-salt diet for the last half of pregnancy (2 weeks) also found that only the nonpregnant rats (treated for the same time period) underwent remodeling, that is, the pregnant animals lacked any structural response to hypertension.<sup>88</sup>

The mechanism by which pregnancy prevents hypertensive remodeling of cerebral arteries is not known but appears to be related to the pregnant state. Furthermore, the consequence of pregnancy preventing hypertensive remodeling of cerebral arteries is not clear but may promote forced dilatation at lower pressures and limit the rightward shift in the autoregulatory curve that would normally occur in response to this duration of hypertension. In addition, it is not known whether preexisting hypertensive remodeling can be reversed by pregnancy. Any reversal of hypertension-induced remodeling may further predispose women with chronic hypertension to eclampsia, because MAP is elevated, but without an increased wall:lumen ratio that is thought to be protective. The effect of pregnancy on hypertensive remodeling and medial hypertrophy of cerebral arteries is interesting and highlights an underlying mechanism by which pregnancy influences cerebrovascular structure in ways that can influence cerebral hemodynamics.

### BBB During Pregnancy and Eclampsia

Understanding how pregnancy affects water flux in the brain is of particular interest given that the neurologic symptoms of

eclampsia have been shown in numerous studies to involve edema formation.<sup>8–18</sup> The brain is a unique organ in how it deals with water flow from the blood.<sup>43,44</sup> For all other tissues there is convective water flow into the tissue with solute between the endothelial cells, and only plasma proteins are retained in the vascular space.<sup>99</sup> The retained protein oncotic pressure offsets the efflux of fluid because of blood hydrostatic pressure and gives rise to Starling's forces.<sup>99</sup> However, morphologically, brain endothelial cells are more similar to epithelial cells than to endothelial cells in peripheral blood vessels in that there is limited molecular transport because of a low rate of fluid-phase endocytosis (that limits transcellular flux) and coupling by high electrical resistance tight junctions (that limits paracellular flux).<sup>100</sup> These morphological features prevent the extravasation of large and small solutes and are considered the BBB.<sup>101,102</sup> The tight junctions of the brain effectively prevent the movement of hydrophilic substances, including plasma proteins and univalent cations, such as  $\text{Na}^+$  and  $\text{K}^+$ .<sup>43,44</sup> This serves to modify Starling's forces such that any movement of water into the brain by normal blood hydrostatic pressure is immediately opposed by the osmotic pressure gradient set up by the ions retained in the vascular lumen.<sup>44</sup> This unique situation prevents vasogenic edema formation under normal conditions and is considered to be a



**Figure 4.** A, Regional CBF in late-pregnant (LP) rats determined using microspheres at normal blood pressure and after an acute elevation in pressure to cause autoregulatory breakthrough. Notice that CBF is increased in response to phenylephrine infusion in both brain regions. B, BBB permeability to Evan's blue, measured in situ in response to phenylephrine infusion to cause autoregulatory breakthrough in the same brain regions as in A. Notice that whereas autoregulatory breakthrough increased BBB permeability in both brain regions, the posterior brain region was significantly more permeable to Evan's blue.

protective role of the BBB.<sup>44</sup> Because of the prominent role of solute permeability in mediating edema formation, the effect of pregnancy on BBB permeability is clearly of interest. In addition, because of the regional heterogeneity in edema formation during eclampsia, being more prominent in the posterior region of the brain, how BBB permeability may be regionally affected by acute hypertension is also important to understand. In vitro studies using isolated and pressurized cerebral arteries found that pregnancy enhances BBB permeability to relatively large (3000 Da) solutes, but only in response to an acute elevation in pressure that caused forced dilatation of myogenic tone.<sup>103</sup> Studies using an in situ perfused brain model found that acute hypertension increased permeability to sodium fluorescein similarly in both nonpregnant and late-pregnant animals, though only the late-pregnant animals developed edema formation.<sup>47</sup> Regional heterogeneity in BBB permeability was found in our own study on late-pregnant rats that used Evan's blue to show that the posterior cerebrum had significantly greater BBB permeability compared with the anterior cerebrum in response to acute

hypertension (Figure 4).<sup>104</sup> This study included only late-gestation animals and suggests that one mechanism by which the posterior brain region is more susceptible to edema is because of enhanced BBB permeability in that region.

#### Aquaporin Expression in Brain During Pregnancy and Its Role in Eclampsia

Although increased BBB permeability can cause vasogenic edema, how pregnancy affects the hydraulic conductivity of the brain may be just as important. The aquaporins (AQPs) are a family of channel-forming transmembrane proteins that facilitate the movement of water, glycerol, and other solutes across the plasma membrane of cells and can influence hydraulic conductivity of the brain tissue.<sup>105–108</sup> In the brain, 3 AQPs, AQP1, AQP4, and AQP9 have been identified.<sup>108–112</sup> AQP4, the predominant AQP in the brain, is mainly localized in the end feet of astrocytes surrounding blood vessels, the glial limitans membranes, and ependyma.<sup>110,111,113,114</sup> Given its location, AQP4 is thought to facilitate the movement of water at the blood–brain interface and between brain and cerebrospinal flu-

id.<sup>108,113,115</sup> Our own studies have demonstrated a substantial (11- to 18-fold) increase in the expression of AQP4 in rat brain during pregnancy,<sup>116</sup> leading to the suggestion that pregnancy alone is a state of altered brain water homeostasis. However, because AQP4 has not been found in cerebral endothelia, it is unlikely to have a role in vasogenic edema formation. A more plausible explanation for AQP4 in vasogenic edema is that it is involved in edema resolution, as has been shown recently in other brain injury models.<sup>117</sup> To date, no studies have examined the role of AQP4 in mediating edema in response to acute hypertension or the role of its increased expression during pregnancy. In addition, how pregnancy affects the other AQPs in the brain is completely unknown but may be important to understanding how water is handled in the brain during injury, such as during eclamptic encephalopathy.

In addition to its role in water homeostasis, AQP4 has been shown to affect K<sup>+</sup> regulation in the brain and to modulate seizure activity. AQP4 knockout mice were shown to have decreased seizure threshold invoked by the chemoconvulsant pentylenetetrazol<sup>118</sup> or to electrically stimulated seizure,<sup>119</sup> a result thought to be mediated by altered K<sup>+</sup> homeostasis in the brain.<sup>120</sup> Increased AQP expression in the brain during pregnancy may be detrimental by lowering the threshold for seizure, the hallmark of eclampsia.<sup>90</sup>

### Animal Models of Eclampsia

Hypertension during pregnancy is a disease specific to bipedal species and, therefore, true animal models of this condition do not exist.<sup>121</sup> However, similar to preeclampsia, there are some useful models that mimic various aspects of eclampsia and provide valuable insight into how edema formation can occur and cause the neurologic symptoms of eclampsia. In particular, models that mimic eclamptic encephalopathy and cause hydrostatic brain edema are likely some of the most useful. These can be used in normal pregnancy and the postpartum state or in combination with models of preeclampsia to further distinguish potential mechanisms of brain edema. It is worth reemphasizing that women who develop eclampsia exhibit a wide spectrum of signs and symptoms ranging from severe hypertension and proteinuria to mild or absent hypertension with no proteinuria.<sup>78–80</sup> Therefore, if studies of eclampsia were limited to models of preeclampsia, one would likely miss important mechanistic insight into the underlying cause of eclampsia.

### Models of Hypertensive Encephalopathy

Because of the similarities in presentation with PRES or hypertensive encephalopathy, models of acute hypertension that have been used extensively as models of hypertensive encephalopathy during pregnancy and the postpartum state can be very useful to understanding how acute elevations in pressure during pregnancy affect CBF autoregulation, CVR, and brain edema. Both nonsurvival and survival models are described below.

#### *Acute Hypertension: Nonsurvival*

One of the most common models of acute hypertension that has been used extensively to investigate hypertensive enceph-

alopathy involves an acute infusion of a pressor agent, such as norepinephrine or phenylephrine, to anesthetized animals.<sup>47,70–74</sup> These agents are chosen because they do not cross the BBB and, therefore, raise MAP by peripheral vasoconstriction.<sup>122</sup> Pressures can be increased beyond autoregulatory breakthrough while measuring CBF, thereby obtaining autoregulation curves (see Figure 1).<sup>47</sup> CBF can be measured indirectly by laser Doppler, which has the advantage that it is a continuous measurement over multiple pressures. The disadvantage is that only relative changes in CBF can be measured. The use of microspheres to measure absolute changes in CBF is more cumbersome and difficult but has the advantage that regional CBF can be measured (eg, posterior versus anterior cerebrum) and CVR can be determined. This model of acute hypertension can also be used in combination with an in situ perfused brain technique for measuring BBB permeability or edema formation, making this a valuable model for understanding how normal pregnancy and the postpartum state affect cerebral hemodynamics, solute permeability, and edema formation. This model can also be used in combination with a model of preeclampsia, such as the reduced uterine placental perfusion model, which contains endothelial dysfunction and oxidative stress.<sup>123</sup> The disadvantage of this acute hypertension technique is that the animals are anesthetized, which may alter cerebral hemodynamics and prevent seizure. In addition, it is difficult to raise pressure for more than several minutes, a short time frame for which the studies can be done.

#### *Acute Hypertension: Survival*

Although currently there are no studies in which a survival model of acute hypertension has been performed during pregnancy, it is conceivable that such a technique could be performed. This would require infusion of a pressor agent in conscious animals, possibly by osmotic pump infusion. The advantage of this approach is that animals do not need to be anesthetized and can be studied for considerably longer time periods. In addition, the time course of edema formation and resolution can be determined as well as whether or not pregnancy affects seizure threshold. The disadvantage is that blood pressure measurements can be difficult.

#### *Dahl Salt-Sensitive Rat*

The Dahl salt-sensitive rat becomes severely hypertensive when fed a high-salt diet (8% NaCl) and will develop the symptoms of hypertensive encephalopathy, including autoregulatory breakthrough, BBB disruption, and edema formation, that result in seizure.<sup>88,124</sup> Although potentially a good model to study the development of seizure in pregnancy because of pathologically elevated blood pressure, it takes several weeks on the high-salt diet to obtain pressures high enough to cause encephalopathy. Because of the short gestation of the rat, the high-salt diet would need to be started before mating to obtain pressures that are at pathologic levels during pregnancy.

### Models of Seizure

Because seizure is the hallmark of eclampsia, models of seizure may be very useful for understanding how pregnancy alone affects seizure threshold. Various animal models of

seizure exist, including genetic models of chronic epilepsy and acute chemically induced seizure.<sup>125,126</sup> It is likely that epileptogenesis during eclampsia is more related to acute brain injury than genetic mutations that cause chronic epilepsy. Therefore, seizure models that are acute and related to vasogenic edema are likely the most useful.<sup>127</sup> Although the relationship between rat and mice models of seizure to the human condition are tenuous, insights from these models to understand how pregnancy and preeclampsia affect seizure threshold would be helpful to understanding the pathology of eclampsia.

### Models of Preeclampsia

There are numerous animal models of preeclampsia that have proven useful to understanding this disease. Animal models of preeclampsia have been reviewed in detail elsewhere<sup>121</sup> and will be discussed here only briefly as they pertain to the cerebral circulation. Some of the maternal symptoms of preeclampsia can be mimicked by placental ischemia (reduced uterine placental perfusion) and NO synthase inhibition, including widespread endothelial dysfunction of the maternal endothelium and oxidative stress. Although we have investigated how NO synthase inhibition affects cerebral artery remodeling and autoregulation of CBF,<sup>47,98</sup> how other models of preeclampsia affect the cerebral circulation is largely unknown. Of particular interest are models that include elevated antiangiogenic factors, such as sFlt-1 and endoglin,<sup>128</sup> as well as reduced uterine placental perfusion. Although none of these models of preeclampsia contain all of the symptoms of the disease, or are spontaneous, understanding how these various models affect the structure and function of the cerebral circulation may provide mechanistic insight into how brain edema forms and promotes the neurologic complications of eclampsia.

### Perspectives

The function of the cerebral circulation is central to the development of eclamptic encephalopathy. Pregnancy alone appears to have a substantial effect on the cerebral circulation, including altering endothelial cell vasodilator production, decreasing CVR, and preventing protective hypertensive remodeling of cerebral arteries. Pregnancy may also affect BBB permeability and increase hydraulic conductivity of the brain, further promoting edema formation when blood pressure is elevated. Understanding how the cerebral circulation is altered during gestation, both under normal condition and in response to preeclampsia, is important to the treatment and prevention of eclampsia.

### Acknowledgments

I would like to thank Ira Bernstein, MD, for his insightful comments and discussions and Frank Faraci, PhD, for all of his continued advice and help with the animal models. I also gratefully acknowledge Lisa Vitullo and Anna Euser, PhD, whose technical expertise is unsurpassed and without whose support much of our work could not be accomplished.

### Sources of Funding

We gratefully acknowledge the support of the National Institute of Neurologic Disorders and Stroke (grant NS045940) and the American Heart Association Established Investigator Award (0540081N).

We also acknowledge the continued support of the Totman Medical Research Trust.

### Disclosures

None.

### References

- Roberts JM, Redman CWG. Pre-eclampsia: more than pregnancy-induced hypertension. *Lancet*. 1993;341:1447-1454.
- Barron WM. Hypertension. In: Barron WM, Lindheimer M, eds. *Medical Disorders of Pregnancy*. St Louis, MO: Mosby Year Book; 1991:1-41.
- Wityk RJ, Pessin MS. Hypertensive encephalopathy. In: Batjer HH, ed. *Cerebrovascular Disease*. Philadelphia, PA: Lippincott Raven Publishers; 1997:97-102.
- Donaldson JO. Eclamptic hypertensive encephalopathy. *Semin Neurol*. 1988;8:230-233.
- Mas J-L, Lamy C. Stroke in pregnancy and the postpartum period. In: Ginsberg MD, Bogousslavsky J, eds. *Cerebrovascular Disease: Pathophysiology, Diagnosis and Management*. Malden, MA: Blackwell Science; 2004:1684-1697.
- Villar MA, Sibai BM. Eclampsia. In: Arias F, ed. *Obstetrics and Gynecology Clinics of North America. High Risk Pregnancy*. Philadelphia, PA: WB Saunders; 1988:356-377.
- Donaldson JO. Eclampsia. In: Donaldson JO, ed. *Neurology of Pregnancy*. London, United Kingdom: WB Saunders; 1989:269-310.
- Zunker P, Happe S, Georgiadis AL, Louwen F, Georgiadis D, Ringelstein EB, Holgreve W. Maternal cerebral hemodynamics in pregnancy-related hypertension. A prospective transcranial Doppler study. *Ultrasound Obstet Gynecol*. 2000;16:179-187.
- Donaldson JO. The brain in eclampsia. *Hypertens Pregnancy*. 1994;13:115-133.
- Dinsdale HB, Mohr JP. Hypertensive Encephalopathy. In: Barnett JMH, Mohr JP, Stein BM, Yatsu FM, eds. *Stroke. Pathophysiology, Diagnosis and Management*. New York, NY: Churchill Livingstone; 1998:869-874.
- Thomas SV. Neurologic aspects of eclampsia. *J Neurol Sci*. 1998;155:37-43.
- Williams KP, Wilson S. Persistence of cerebral hemodynamic changes in patients with eclampsia: a report of three cases. *Am J Obstet Gynecol*. 1999;181:1162-1165.
- Kanki T, Tsukimori K, Mihara F, Nakano H. Diffusion-weighted images and vasogenic edema in eclampsia. *Obstet Gynecol*. 1999;93:821-823.
- Manfredi M, Beltramello A, Bongiovanni LG, Polo A, Pistoia L, Rizzuto N. Eclamptic encephalopathy: imaging and pathogenetic considerations. *Acta Neurol Scand*. 1997;96:277-282.
- Koch S, Rabinstein A, Falcone S, Forteza A. Diffusion-weighted imaging shows cytotoxic and vasogenic edema in eclampsia. *Am J Neurorad*. 2001;22:1068-1070.
- Richards AM, Moodley J, Graham DI, Bullock MR. Active management of the unconscious eclamptic patient. *Br J Obstet Gynecol*. 1986;93:554-562.
- Richards AM, Graham DI, Bullock MR. Clinical pathological study of neurologic complications due to hypertensive disorders of pregnancy. *J Neurol Neurosurg Psychiatr*. 1988;51:416-421.
- Schwartz RB, Jones KM, Kalina P, Gajakian RL, Mantello MT, Garada B, Holman BL. Hypertensive encephalopathy: findings on CT, MR-imaging, and SPECT-imaging in 14 cases. *Am J Radiol*. 1992;159:379-383.
- Mackey K, Meyer MC, Stirewalt WS, Starcher BC, McLaughlin MK. Composition and mechanics of mesenteric resistance arteries from pregnant rats. *Am J Physiol*. 1992;263:R2-R8.
- Hermsteiner M, Zoltan DR, Kunzel W. The vasoconstrictor response of uterine and mesenteric resistance arteries is differentially altered in the course of pregnancy. *Eur J Obstet Gynecol Reprod Biol*. 2001;100:29-35.
- Cipolla MJ, Osol G. Hypertrophic and hyperplastic effects of pregnancy on the uterine arterial wall. *Am J Obstet Gynecol*. 1994;171:805-811.
- Gilson GJ, Mosher MD, Conrad KP. Systemic hemodynamics and oxygen transport during pregnancy in chronically instrumented, conscious rats. *Am J Physiol*. 1992;263:H1911-H1918.
- Easton DJ. Severe preeclampsia/eclampsia hypertensive encephalopathy of pregnancy? *Cerebrovasc Dis*. 1998;8:53-58.
- Port JD, Beauchamp NJ. Reversible intracerebral pathologic entities mediated by vascular autoregulatory dysfunction. *Radiographics*. 1998;18:253-267.

25. Digre KB, Varner MW, Osborn AG, Crawford S. Cranial magnetic resonance imaging in severe preeclampsia vs. eclampsia. *Arch Neurol.* 1993;50:399–406.
26. Schaefer PW, Buonnano FS, Gonzalez RG, Schwamm LH. Diffusion-weighted imaging discriminates between cytotoxic and vasogenic edema in patients with eclampsia. *Stroke.* 1997;28:1082–1085.
27. Schwartz RB, Mulern RV, Grudbjartsson H, Jolesz F. Diffusion-weighted imaging in hypertensive encephalopathy: clues to pathogenesis. *Am J Neuroradiol.* 1998;19:859–862.
28. Shah AK, Whitty JE. Brain MRI in peripartum seizures: usefulness of combined T2 and diffusion-weighted MR imaging. *J Neurol Sci.* 1999;166:122–125.
29. Pizon AF, Wolfson AB. Postpartum focal neurologic deficits: posterior leukoencephalopathy syndrome. *J Emergency Med.* 2005;29:163–166.
30. Servillo G, Striano P, Striano S. Posterior reversible encephalopathy syndrome (PRES) in obstetric critically ill patients. *Intensive Care Med.* 2003;29:2323–2326.
31. Mirza A. Posterior reversible encephalopathy syndrome: a variant of hypertensive encephalopathy. *J Clin Neurosci.* 2006;590–595.
32. Demirtaş, Gelal F, Dirim V, Demirtaş LO, Uluç E, Balolu A. Cranial MR imaging with clinical correlation in preeclampsia and eclampsia. *Neuroradiology.* 2005;11:189–194.
33. Engelter ST, Provenzale JM, Petrella JR. Assessment of vasogenic edema in eclampsia using diffusion imaging. *Neuroradiology.* 2000;42:818–820.
34. Klatzo I. Neuropathologic aspects of brain edema. *J Neuropathol Exp Neurol.* 1967;26:1–14.
35. Hinchey J, Chaves C, Appignani B, Breen J, Pao L, Wang A, Pessin MS, Lamy C, Mas JL, Caplan LR. A reversible posterior encephalopathy syndrome. *N Engl J Med.* 1996;334:494–500.
36. Iannotti F, Hoff JT, Schielke GP. Brain tissue pressure in focal cerebral ischemia. *J Neurosurg.* 1985;62:83–89.
37. Zeeman GG, Fleckenstein J, Twickler DM, Cunningham FG. Cerebral infarction in eclampsia. *Am J Obstet Gynecol.* 2004;190:714–720.
38. Striano P, Striano S, Tortora F, De Robertis E, Palumbo D, Elefante A, Servillo G. Clinical spectrum and critical care management of posterior reversible encephalopathy syndrome. *Med Sci Monitor.* 2005;11:CR549–CR553.
39. Schwartz RB, Bravo SM, Klufas RA, Hsu L, Barnes PD, Robson CD, Antin JH. Cyclosporine neurotoxicity and its relationship to hypertensive encephalopathy: CT and MR findings in 16 cases. *Am J Roentgenol.* 1995;165:627–631.
40. Ishii S, Koike J, Hatashita S. Brain edema in hypertensive intracranial hemorrhage. In: Mizukami M, ed. *Hypertensive Intracerebral Hemorrhage.* New York, NY: Raven Press; 1983.
41. Hatashita S, Koike J, Sonokawa T, Ishii S. Cerebral edema associated with craniectomy and arterial hypertension. *Stroke.* 1985;16:661–668.
42. Shima K. Hydrostatic brain edema: basic mechanisms and clinical aspect. *Acta Neurochir.* 2003;86(suppl):17–20.
43. Rapoport SI. Brain edema and the blood-brain barrier. In: Welch KMA, Caplan LR, Reis DJ, Siesjö BK, Weir B, eds. *Primer on Cerebrovascular Disease.* San Diego, CA: Academic Press; 1997:25–28.
44. Kimelberg HK. Water homeostasis in the brain: basic concepts. *Neuroscience.* 2004;129:851–860.
45. Umezawa H, Shima K, Chigasaki H, Sato K, Ishii S. Local cerebral blood flow and glucose metabolism in hydrostatic brain edema. *Acta Neurochir.* 1990;51 (suppl):351–353.
46. Koike J. Permeability change of cerebral vessels in acute hypertension and external decompression. *Neurol Med Chir (Tokyo).* 1983;23:325–335.
47. Euser AG, Cipolla MJ. Cerebral blood flow autoregulation and edema formation during pregnancy in anesthetized rats. *Hypertension.* 2007;49:334–340.
48. Heistad DD, Kontos HA. The Cardiovascular System III. In: Berne RN, Sperelakis N, eds. *Handbook of Physiology.* Bethesda, MD: American Physiological Society; 1979:137–182.
49. Phillips SJ, Whisnant JP. Hypertension and the brain. *Arch Intern Med.* 1992;152:938–945.
50. Busija DW, Heistad DD. Factors involved in the physiological regulation of the cerebral circulation. *Rev Physiol Biochem Pharmacol.* 1984;101:161–211.
51. Johansson B, Li C-L, Olsson Y, Klatzo I. Effect of acute arterial hypertension on the blood-brain barrier to protein tracers. *Acta Neuropath.* 1970;16:117–124.
52. Kontos HA, Wei EP, Navari RM, Levasseur JE, Rosenblum WI, Patterson JL Jr. Responses of cerebral arteries and arterioles to acute hypotension and hypertension. *Am J Physiol.* 1978;234:H371–H383.
53. Kontos HA, Wei EP, Dietrich WE, Navari RM, Povlishock JT, Ghatak NR, Ellis EF, Patterson JL Jr. Mechanism of cerebral arteriolar abnormalities after acute hypertension. *Am J Physiol.* 1981;240:H511–H527.
54. Immink RV, van Montfrans GA, Stam J, Karemaker JM, Diamant M, van Lieshout JJ. Dynamic cerebral autoregulation in acute lacunar and middle cerebral artery territory ischemic stroke. *Stroke.* 2005;36:2595–2600.
55. Wintermark M, Chioloro R, Van Melle G, Revelly JP, Porchet F, Regli L, Maeder P, Meuli R, Schnyder P. Cerebral vascular autoregulation assessed by perfusion-CT in severe head trauma patients. *J Neuroradiol.* 2006;33:27–37.
56. Schwartz RB, Feske SK, Polak JF, DeGirolami U, Iaia A, Beckner KM, Bravo SM, Klufas RA, Chai RY, Repke JT. Pre-eclampsia-eclampsia: clinical and neuroradiologic correlates and insights into the pathogenesis of hypertensive encephalopathy. *Radiology.* 2000;217:371–376.
57. Robson SC, Hunter S, Boys RJ, Dunlop W. Serial study of factors influencing changes in cardiac output during human pregnancy. *Am J Physiol.* 1989;256:H1060–H1065.
58. Clapp JF III, Capeless E. Cardiovascular function before, during and after the first and subsequent pregnancies. *Am J Cardiol.* 1997;80:1469–1473.
59. Aaslid R, Lundar R, Lindegaard K-F, Nornes H. Estimation of cerebral perfusion pressure from arterial blood pressure and transcranial Doppler recordings. In: Miller JD, Teasdale GM, Rowan JO, Galbraith SL, Mendelow AD, eds. *Intracranial Pressure VI.* Berlin, Heidelberg, Germany: Springer-Verlag; 1986:226–229.
60. Belfort MA, Tooke-Miller C, Allen JC, Saade GR, Dildy GA, Grunewald C, Nisell H, Herd JA. Changes in flow velocity, resistance indices, and cerebral perfusion pressure in the maternal middle cerebral artery distribution during pregnancy. *Acta Obstet Gynecol Scand.* 2001;80:104–112.
61. Kontos HA. Validity of cerebral arterial blood flow calculations from velocity measurements. *Stroke.* 1989;20:1–3.
62. Zeeman GG, Hatab HR, Twickler DM. Maternal cerebral blood flow changes in pregnancy. *Am J Obstet Gynecol.* 2003;189:968–972.
63. Williams K, Wilson S. Maternal middle cerebral artery blood flow velocity variation with gestational age. *Obstet Gynecol.* 1994;84:445–448.
64. Serra-Serra V, Kyle PM, Chandran R, Redman CWG. Maternal middle cerebral velocimetry in normal pregnancy and postpartum. *Br J Obstet Gynaecol.* 1997;104:904–909.
65. Sherman RW, Bowie RA, Henfrey MME, Mahajan RP, Bogod D. Cerebral haemodynamics in pregnancy and pre-eclampsia as assessed by transcranial Doppler ultrasonography. *Br J Anaesth.* 2002;89:687–692.
66. Belfort MA, Varner MW, Dizon-Townson DS, Grunewald C, Nishell H. Cerebral perfusion pressure, and not cerebral blood flow, may be the critical determinant of intracranial injury in preeclampsia: a new hypothesis. *Am J Obstet Gynecol.* 2002;187:626–634.
67. Riskin-Mashiah S, Belfort MA, Saade GR, Herd JA. Cerebrovascular reactivity in normal pregnancy and preeclampsia. *Obstet Gynecol.* 2001;98:827–832.
68. Williams KP, Wilson S. Variation in cerebral perfusion pressure of different hypertensive states in pregnancy. *Am J Obstet Gynecol.* 1998;179:120–123.
69. Zeeman GG, Hatab M, Twickler DM. Increased cerebral blood flow in preeclampsia with magnetic resonance imaging. *Am J Obstet Gynecol.* 2004;191:1425–1429.
70. Johansson BB. Effect of an acute increase of the intravascular pressure on the blood-brain barrier. *Stroke.* 1978;9:588–590.
71. Mayhan WG, Faraci FM, Heistad DD. Effects of vasodilatation and acidosis on the blood-brain barrier. *Microvasc Res.* 1988;35:179–192.
72. Auer L. The role of cerebral perfusion pressure as origin of brain edema in acute arterial hypertension. *Eur Neurol.* 1977;15:153–156.
73. Faraci FM, Mayhan WG, Heistad DD. Segmental vascular responses to acute hypertension in cerebrum and brainstem. *Am J Physiol.* 1987;252:H738–H742.
74. Baumbach GL, Heistad DD. Heterogeneity of brain blood flow and permeability during acute hypertension. *Am J Physiol.* 1985;249:H629–H637.
75. Johansson B. The blood-brain barrier and cerebral blood flow in acute hypertension. *Acta Med Scand.* 1983;678(suppl):107–112.
76. Bill A, Linder J. Sympathetic control of cerebral blood flow in acute arterial hypertension. *Acta Physiol Scand.* 1976;96:114–121.
77. Johansson B. Regional changes of cerebral blood flow in acute hypertension in cats. *Acta Neurol Scand.* 1974;50:366–372.

78. Sabai BM. Eclampsia. VI. Maternal-perinatal outcome in 254 consecutive cases. *Am J Obstet Gynecol.* 1990;163:1049–1055.
79. Mattar F, Sabai BM. Eclampsia. VIII. Risk factors for maternal mortality. *Am J Obstet Gynecol.* 2000;182:307–312.
80. Douglas KA, Redman CWG. Eclampsia in the United Kingdom. *BMJ.* 1994;309:1395–1400.
81. Katz VL, Farmer R, Kuller JA. Preeclampsia into eclampsia: toward a new paradigm. *Am J Obstet Gynecol.* 2000;182:1389–1396.
82. Zatik J, Major R, Aranyozi J, Molnar C, Limburg M, Fulesdi B. Assessment of cerebral hemodynamics during roll over test in healthy, pregnant women and those with pre-eclampsia. *Br J Obstet Gynaecol.* 2001;108:353–358.
83. Oehm E, Hetzel A, Els T, Berlis A, Keck C, Will H-G, Reinhard M. Cerebral hemodynamics and autoregulation in reversible posterior leukoencephalopathy syndrome caused by pre-/eclampsia. *Cerebrovasc Dis.* 2006;22:204–208.
84. Oehm E, Reinhard M, Keck C, Els T, Spreer J, Hetzel A. Impaired dynamic cerebral autoregulation in eclampsia. *Ultrasound Obstet Gynecol.* 2003;22:395–398.
85. Cipolla MJ, Vitullo L, McKinnon J. Cerebral artery reactivity changes during pregnancy and postpartum: a role in eclampsia? *Am J Physiol.* 2004;286:H2127–H2132.
86. Wahl M, Schilling L. Regulation of cerebral blood flow - a brief review. *Acta Neurochir (Wien).* 1993;59(suppl):3–10.
87. Cipolla MJ, Li R, Vitullo L. Perivascular innervation of penetrating brain parenchymal arterioles. *J Cardiovasc Pharmacol.* 2004;44:1–8.
88. Aukes AM, Vitullo L, Zeeman GG, Cipolla MJ. Pregnancy prevents hypertensive remodeling and decreases myogenic reactivity in posterior cerebral arteries from Dahl salt-sensitive rats: a role in eclampsia? *Am J Physiol.* 2007;292:H1071–H1076.
89. Bolay H, Reuter U, Dunn AK, Huang Z, Boas DA, Moskowitz MA. Intrinsic brain activity triggers trigeminal meningeal afferents in a migraine model. *Nat Med.* 2002;8:136–142.
90. Sibai BM. Diagnosis, prevention, and management of eclampsia. *Obstet Gynecol.* 2005;105:402–410.
91. Sadoshima S, Fujii K, Yao H, Ibayashi S, Fujishima M. Effect of chronic sympathetic denervation on cerebrovascular hypertrophy during the development of hypertension in rats. *Brain Res.* 1986;379:205–209.
92. Baumbach GL, Dobrin PB, Hart MN, Heistad DD. Mechanics of cerebral arterioles in hypertensive rats. *Circ Res.* 1988;62:56–64.
93. Heistad DD, Baumbach GL. Cerebral vascular changes during chronic hypertension: good guys and bad guys. *J Hypertens.* 1992;10(suppl 7):S71–S75.
94. Baumbach GL, Heistad DD. Cerebral circulation in chronic arterial hypertension. *Hypertension.* 1988;12:89–95.
95. Chillon J-M, Ghoniem S, Baumbach GL. Effects of chronic nitric oxide synthase inhibition on cerebral arterioles in rats. *Hypertension.* 1997;30:1097–1104.
96. Morreau P, Takase H, Kung CF, van Rooijen M, Schaffner T, Luscher TF. Structure and function of the rat basilar artery during chronic nitric oxide synthase inhibition. *Stroke.* 1995;26:1922–1929.
97. Werber AH, Heistad DD. Effects of chronic hypertension and sympathetic nerves on the cerebral microvasculature of stroke-prone spontaneously hypertensive rats. *Circ Res.* 1984;55:268–294.
98. Cipolla MJ, DeLance N, Vitullo L. Pregnancy prevents hypertensive remodeling of cerebral arteries: A potential role in the development of eclampsia. *Hypertension.* 2006;47:619–626.
99. Berne RM, Levy MN. The microcirculation and lymphatics. In: Berne RM, Levy MN, Koepfen BM, Stanton BA, eds. *Physiology.* St Louis, MO: Mosby; 1998:429–441.
100. Kniessel U, Wolburg H. Tight junctions of the blood-brain barrier. *Cell Mol Neurobiol.* 2000;20:57–76.
101. Betz AL, Dietrich WD. Blood-brain barrier dysfunction in cerebral ischemia. In: Ginsberg MD, Bogousslavsky J, eds. *Cerebrovascular Disease: Pathophysiology, Diagnosis and Management.* Malden, MA: Blackwell Science; 1998:358–370.
102. Wahl M, Unterberg A, Baethmann A, Schilling L. Mediators of blood-brain barrier dysfunction and formation of vasogenic brain edema. *J Cereb Blood Flow Metab.* 1988;8:621–634.
103. Cipolla MJ, Vitullo L, DeLance N, Hammer E. The cerebral endothelium during pregnancy: a potential role in the development of eclampsia. *Endothelium.* 2005;12:1–5.
104. Cipolla MJ, Vitullo L, Euser AG. Differential cerebral blood flow and blood-brain barrier permeability during acute hypertension in pregnancy and its role in eclampsia. *Reproductive Sci.* 2007;14(1 suppl):220A.
105. Ishibashi K, Kuwahara M, Sasaki S. Molecular biology of aquaporins. *Rev Physiol Biochem Pharmacol.* 2000;141:1–32.
106. Agre P, Bonhivers M, Borgnia MJ. The aquaporins, blueprints for cellular plumbing systems. *J Biol Chem.* 1998;273:14659–14662.
107. Verkman AS. Aquaporin water channels and endothelial cell function. *J Anat.* 2002;200:617–627.
108. Amiry-Moghaddam M, Ottersen OP. The molecular basis of water transport in the brain. *Nat Neurosci.* 2003;4:991–1001.
109. Nielsen S, Smith BL, Christensen EL, Agre P. Distribution of the aquaporin CHIP in secretory and resorptive epithelia and capillary endothelia. *Proc Natl Acad Sci U S A.* 1993;90:7275–7279.
110. Hasegawa H, Ma T, Skach W, Matthy MA, Verkman AS. Molecular cloning of a mercurial-insensitive water channel expressed in selected water-transporting tissues. *J Biol Chem.* 1994;269:5497–5500.
111. Jung JS, Bhat RV, Preston GM, Guggino WB, Baraban JM, Agre P. Molecular characterization of an aquaporin cDNA from brain: candidate osmoreceptor and regulator of water balance. *Proc Natl Acad Sci U S A.* 1994;91:13052–13056.
112. Elkjaer ML, Vajda Z, Nejsum LN, Kwon TH, Jensen UB, Amiry-Moghaddam M, Frokiaer J, Nielsen S. Immunolocalization of AQP9 in liver, epididymis, testis, spleen, and brain. *Biochem Biophys Res Comm.* 2000;276:1118–1128.
113. Nielsen S, Nagelhus EA, Amiry-Moghaddam M, Bourque C, Agre P, Ottersen OP. Specialized membrane domains for water transport in glial cells: High-resolution immunogold cytochemistry of aquaporin-4 in rat brain. *J Neurosci.* 1997;17:171–180.
114. Amiry-Moghaddam M, Xue R, Haug FM, Neely JD, Bhardwaj A, Agre P, Adams ME, Froehner SC, Mori S, Ottersen OP. Alpha-syntrophin deletion removes the perivascular but not endothelial pool of aquaporin-4 at the blood-brain barrier and delays the development of brain edema in an experimental model of acute hyponatremia. *FASEB J.* 2004;18:542–544.
115. Amiry-Moghaddam M, Otuska T, Hurn PD, Traystman RJ, Haug F-M, Froehner SC, Adams ME, Neely JD, Agre P, Ottersen OP, Bhardwaj A. An alpha-syntrophin-dependent pool of AQP4 in astroglial end-feet confers bidirectional water flow between blood and brain. *Proc Natl Acad Sci U S A.* 2003;100:2106–2111.
116. Quick AM, Cipolla MJ. Pregnancy-induced upregulation of aquaporin-4 protein in brain and its role in eclampsia. *FASEB J.* 2005;19:170–175.
117. Papadopoulos MC, Manely GT, Krishna S, Verkman AS. Aquaporin-4 facilitates reabsorption of excess fluid in vasogenic brain edema. *FASEB J.* 2004;18:1291–1293.
118. Binder DK, Oshio K, Ma T, Verkman AS, Manley GT. Increased seizure duration in mice lacking aquaporin-4 water channels. *Acta Neurochir.* 2006;96(suppl):389–392.
119. Binder DK, Yao X, Verkman AS, Manley GT. Increased seizure threshold in mice lacking aquaporin-4 water channels. *Neuroreport.* 2004;15:259–262.
120. Binder DK, Yao X, Zador Z, Sick T, Verkman AS, Manley GT. Increased seizure duration and slowed potassium kinetics in mice lacking aquaporin-4 water channels. *Glia.* 2006;53:631–636.
121. Podjarny E, Losonczy G, Baylis C. Animal models of preeclampsia. *Semin Perinat.* 2004;24:596–606.
122. Duckles SP, Bevan JA. Pharmacologic characterization of adrenergic receptors of rabbit cerebral artery in vitro. *J Pharmacol Exp Ther.* 1976;197:371–377.
123. Granger JP, Alexander BT, Llinas MT, Bennet WA, Khalil RA. Pathophysiology of hypertension during preeclampsia linking placental ischemia with endothelial dysfunction. *Hypertension.* 2001;38:718–722.
124. Smeda JS, Payne GW. Alterations in autoregulatory and myogenic function in the cerebrovasculature of Dahl salt-sensitive rats. *Stroke.* 2003;34:1484–1490.
125. Holmes GL. Models for generalized seizures. *Suppl Clin Neurophysiol.* 2004;57:415–424.
126. Jefferys JG. Models and mechanisms of experimental epilepsies. *Epilepsia.* 2003;44(suppl 12):44–51.
127. Oby E, Janigro D. The blood-brain barrier and epilepsy. *Epilepsia.* 2006;47:1761–1774.
128. Venkatesha A, Toporsian M, Lam C, Hanai J-I, Mammoto T, Kim YM, Bdoah Y, Lim K-H, Yuan H-T, Libermann TA, Stillman IE, Roberts D, D'Amore PA, Epstein FH, Sellke FW, Romero R, Sukhatme VP, Letarte M, Karumanchi SA. Soluble englobin contributes to the pathogenesis of preeclampsia. *Nat Med.* 2006;12:642–649.