

Axial Rotation Component of Thoracic Scoliosis

Ian A. F. Stokes

Department of Orthopaedics and Rehabilitation, University of Vermont, Burlington, Vermont, U.S.A.

Summary: The axial rotation (rotation about a vertical axis) of the vertebrae, of the ribs, and of the back surface are components of the deformity recognized clinically as the "rib hump" in thoracic scoliosis. Relationships of these rotations to the lateral deviation and lateral curvature of the spine were studied in 40 patients with idiopathic scoliosis. Stereoradiographs of the spine and rib cage were used to measure three components of axial rotation: rotation of the vertebrae, of the rib cage, and of the plane of maximum curvature of the spine. Stereotopographs of the back surface were digitized to measure the axial rotation of the back surface.

In individual patients, there were high correlations of all components of axial rotation at each spinal level with the corresponding vertebral lateral deviation from the spinal axis. By regression analyses of the maximum values of each rotation in each curve, the rotation of the apex vertebra was found to be generally of lesser magnitude than the rotation of the plane of maximum curvature of the spine and in an opposite sense in kyphotic curves. The rib cage rotation was generally of lesser magnitude than the vertebra rotation, and the back surface rotation was less than both of these skeletal rotations.

Vertebra rotation correlated most closely with lateral deviation of the spine. Simple segmental coupling of axial rotation and lateral bending could not be responsible for this axial rotation. **Key Words:** Scoliosis—Axial rotation—Ribs—Thorax—Biomechanics.

The scoliosis deformity is most commonly described as lateral deviation and resulting lateral curvature of the spine. The magnitude of the scoliosis is measured by the Cobb angle and most treatments are directed towards stabilizing or reducing the lateral curve. However, the deformity also manifests itself as a rotational asymmetry about the vertical axis, with axial rotation of the vertebrae (3,4,8,17,29), of the plane of maximum curvature of the spine (the plane containing the greatest number of vertebrae in a curve) (16,18,25), and of the back surface, which becomes elevated on one side, producing the "rib hump" by which the deformity is most frequently recognized clinically (5,12,28) and

subjectively by patients. "Rib hump" is a difficult component of the deformity to correct (4,11). The mechanisms by which these various axial rotational components of the deformity interact is poorly understood, but axial rotation has been implicated in the etiology of scoliosis. It has been proposed that abnormal sagittal plane curvature of the spine creates an instability leading to lateral deviation in combination with lateral bending (7,8,10,22). In the thoracic region, Roaf (19) implicated forces from the ribs in causing the rotation, which he considered as an important component in producing the deformity. Mathematical modeling has shown how the ribs may increase the stiffness of the thoracic spine during progression of scoliosis (1,20).

The association of two or more degrees of freedom of motion between vertebrae has been defined as coupling (15), and has been implicated in the de-

Address correspondence and reprint requests to Dr. I. A. F. Stokes at Department of Orthopaedics and Rehabilitation, University of Vermont, Burlington, VT 05405, U.S.A.

velopment of scoliosis (29). Arkin (2) noted a tendency for lateral bending of normal spines to produce a spinal shape similar to scoliosis, especially when the spine was in flexion. He attributed this to tension in soft tissue components that cross several interspaces. However, Roaf (19) noted that the direction of the axial rotation in scoliosis has to be in an opposite sense above and below the curve apex to restore neutral rotation at the inflection points. Examination of radiographs shows that the direction of relative axial rotation between vertebrae is in an opposite sense above and below the curve apex, while the direction of relative lateral bending remains the same. Thus, simple "coupling" of lateral bending and axial rotation in intervertebral joints cannot produce a spinal curvature in which the maximum axial rotation is at the curve apex. Coupling of lateral bending and axial rotation at each segmental level would instead produce maximum curvature at the inflection points of the curve (Fig. 1).

Lordosis or kyphosis combine with the lateral curvature in scoliosis so that the vertebrae lie in a plane that is intermediate between the frontal and the sagittal planes. This plane has been termed the plane of maximum spinal deformity (9,18). In order to record the spinal shape in this plane, Peloux et al. (16) described a preferred plane for radiographic projection aligned with the apical vertebra and the two end vertebrae of the scoliosis curve. Perdriolle

and Vidal (17) also described an auxiliary radiographic projection, but rotated their radiographic planes instead by the amount of the axial rotation of the apical vertebra. However, these two auxiliary planes of projection of the spine have been shown to be rotated by quite different amounts, and often are rotated in opposite directions relative to the anatomical planes (25).

The objective of this study was to examine the source of the "rib hump" rotation and its relationship to the spinal deformity. The aims were to quantify the relationships between the axial rotation of the vertebrae, of the back surface, of the rib cage, and of the plane of maximum curvature of the thoracic spine, and also to determine the relationship of these rotations to the magnitude of the scoliosis deformity.

METHODS

Patient Group

Stereoradiographs were made of 40 patients who had thoracic or thoracolumbar scoliosis (mean Cobb angle of 30°, range of 10° to 64°). The radiographically determined curve apices were between T4 and T12, with the greatest number of curves (26 curves) having an apex at T7 or T8. One patient in this group had two scoliosis curves in the thoracic region—a left curve of 24° Cobb with apex at T4 and a right curve of 20° Cobb with the apex at T9. Therefore, 41 curves were analyzed.

Radiographic Measurements

Stereoradiographs of each patient were used to generate computerized measurements of the three-dimensional shape of the spine and of the rib cage. At radiography, the patients were positioned against four pads: two aligned with the anterior spines of the ilia, and two with the clavicles, so that anatomic planes passing through these bony features were parallel to the film plane. Landmarks on the vertebrae (endplate centers and bases of pedicles) were marked on each of the two resulting films, their positions were digitized, and the cartesian coordinates were stored in a computer file. The method of Stokes et al. (25) was then used to compute the three-dimensional coordinates of these landmarks using x-ray stereophotogrammetry.

For each vertebra in the thoracic spine, the lateral deviation was measured as the horizontal dis-

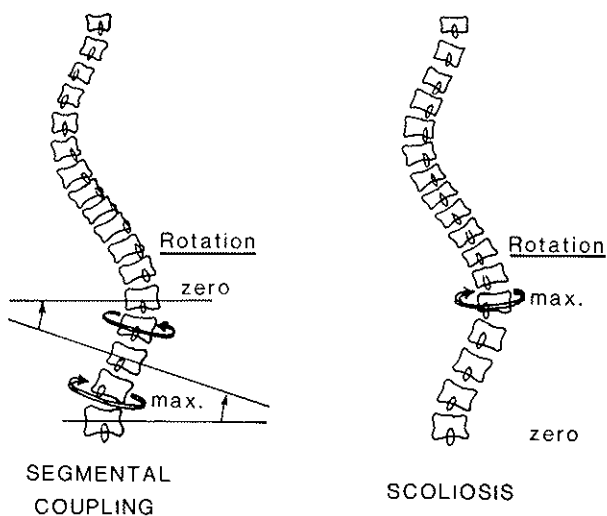


FIG. 1. Left: The axial rotation would be maximal at inflection points if the rotation were produced solely by "coupling" of the rotation with lateral bending in intervertebral joints. Right: The axial rotation of vertebrae is maximal at the curve apex in scoliosis.

tance from the center of the vertebral body to a spinal axis that passed through the bodies of T1 and L5.

Spinal curvature in the frontal plane was calculated by a computerized method based on the Cobb method in which a smooth mathematical curve was first fitted through the frontal plane projections of the coordinates of the centers of the vertebral bodies. Points of inflection in this curve were located, and the angle subtended by perpendiculars to the curve at these inflection points was measured as the "computer Cobb angle" (25). The end vertebrae of the frontal plane scoliosis were then used to identify the tangential points in the lateral projection of the spinal curve, which provided a measurement of kyphosis or lordosis in the region of the spine bounded by the end vertebrae.

Two measurements of spinal axial rotation were then made: "vertebra rotation" and "rotation of the plane of maximum curvature" of the spine. In both cases, a sign convention was adopted such that clockwise angles were positive as viewed from above. Vertebra rotation was measured by the method of Stokes et al. (24), with measurement error of less than 7°. This method uses the positions of the pedicle images relative to the positions of the vertebral body center, with a correction factor based on the anteroposterior distance between the pedicles and vertebral body center.

The "rotation of plane of maximum curvature" (25) of the part of each spine defined by the end vertebrae of the scoliosis curve was found by projecting the spine sequentially onto planes rotated about a vertical axis. The computer program calculated the spinal curvature, based on the perpendiculars to the curve at the end vertebrae, at each rotation. The axial rotation at which this curvature became a maximum was noted, with the patient's sagittal plane as the origin for measurement.

"Posterior rib rotation" was measured from reconstructions of the shapes of the ribs, which were calculated from the digitized stereoradiograph images of the midlines of the ribs by the method of Dansereau and Stokes (6) (Fig. 2). This method uses an iterative computer program to find a line whose projection onto the two radiographic planes best matches the digitized midlines. The accuracy and precision of the reconstruction are about ± 2 mm (6). Posterior rib rotation was measured at each anatomical level as the axial rotation relative to the frontal plane of a line drawn tangentially to the projection of each pair of ribs onto a horizontal plane,

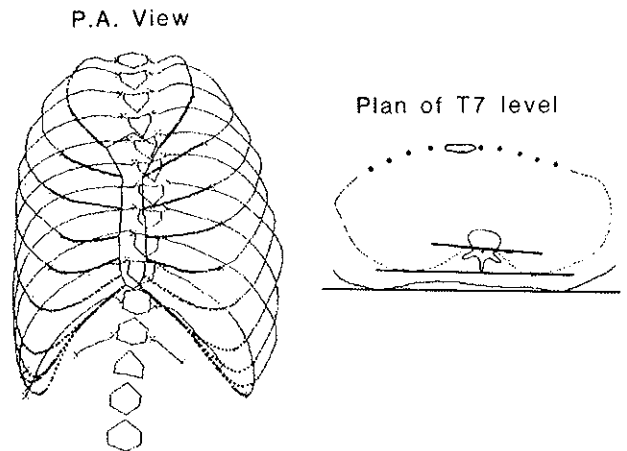


FIG. 2. Example of a rib cage reconstructed from stereoradiographs. The reconstruction was computed from digitized coordinates of the radiographs of a patient with a 27° Cobb scoliosis, with the apex at T7. In the plan view, the lines representing the rib midlines and the back surface cross-section were obtained from the computerized reconstructions; the vertebra, the sternum, and the lines indicating rotation measurements have been drawn in by hand.

as shown in Fig. 3. This method was used because it was similar to the method for measuring the rotation of the corresponding back surface.

Back Surface Rotation

Immediately after radiography, the surface shape of each patient's back was recorded by a projected

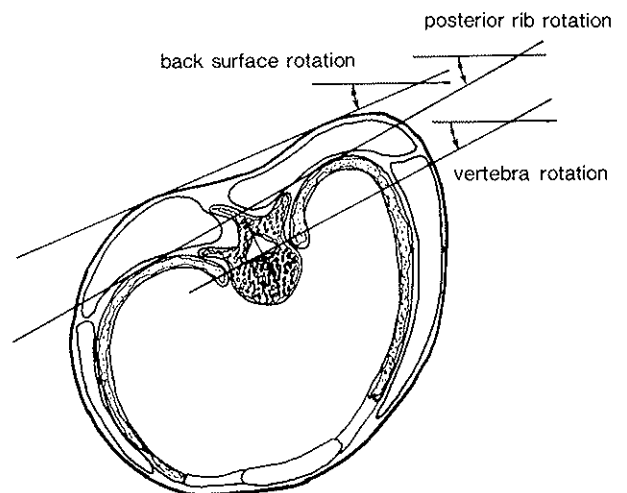


FIG. 3. Projection onto a horizontal plane of a segmental level consisting of a vertebra, the ribs, and the back surface, illustrating the method of measuring "back surface rotation," "posterior rib rotation," and "vertebra rotation." All rotations were measured about a vertical axis, with positive values assigned to clockwise rotations (as seen from above).

raster stereophotographic technique (23,26). Subsequently, the double tangent method was used to determine the rotation of a horizontal plane cross section made through this back surface at the level of each vertebra (Fig. 3). This measurement was termed "back surface rotation." The precision of this measurement was 4° of rotation (27).

RESULTS

Measurements of each patient were first examined to determine the anatomical level of the maximum of each measurement of trunkal asymmetry. The maximum vertebra rotation, back surface rotation, and rib posterior cage rotation all occurred close to the apex of the scoliosis. The vertebra having the greatest axial rotation was at the apex of the scoliosis curve, or within two vertebral levels of it, as was also the maximum posterior rib rotation. The maximum back surface rotation was found to be at a level between two vertebrae above the apex and three vertebrae below it. The maximum of each axial rotation measurement in each curve was noted for subsequent analysis.

The Plane of Maximum Curvature

The plane of maximum curvature was rotated counterclockwise (as seen from above) from the sagittal plane in 29 cases of right convex curves in a kyphotic part of the spine. The converse occurred for six left convex curves. Six curves were in a straight or slightly lordotic region of the spine, as seen in the sagittal projection, so in these cases the plane of maximum curvature was very close to the frontal plane. The amount of the rotation of the plane of maximum curvature correlated with the degree of scoliosis (Cobb angle) with a correlation coefficient of $r = -0.71$. In this analysis, a sign convention was used such that a scoliosis convex to the left side was assigned a negative Cobb angle. The linear regression coefficient was -1.7 , meaning that on average the rotation of the plane of maximum curvature was -1.7 times the frontal plane Cobb angle in degrees.

Correlations Between Axial Rotational and Other Components of Thoracic Scoliosis

Within each curve, a correlation between the axial rotational components at each segmental level

and the lateral deviation of the corresponding vertebra was found. Figure 4 shows an example of this relationship. Statistically, the median correlation in these 40 patients between vertebra deviation and vertebra rotation was 0.72; between vertebra deviation and back surface rotation it was 0.79; and between vertebra deviation and posterior rib rotation it was 0.83. In subsequent analyses, each curve was represented by the maximum or apical value of each axial rotation.

Correlations between measurements of maximum axial rotation and other measures of spinal asymmetry are summarized in Table 1. High correlations between all three axial rotations were found. The slopes of regression lines in Fig. 5 show that statistically (although not in all individual cases) the posterior rib rotation was of lesser magnitude than the vertebra rotation, and the back surface rotation was less than both of these skeletal rotations. In this group of patients, the mean vertebra rotation was 7.6°, the mean posterior rib rotation was 6.5°, and the mean back surface rotation was 5.1° (based on absolute values of apex values from each curve). These mean values demonstrated the same trend, with the posterior rib rotations having magnitudes intermediate between those of the vertebral rotation and the back surface rotation, on average. Since the mean Cobb angle of the curves studied was 30°, all of the axial rotations were considerably less than this measure of spinal asymmetry.

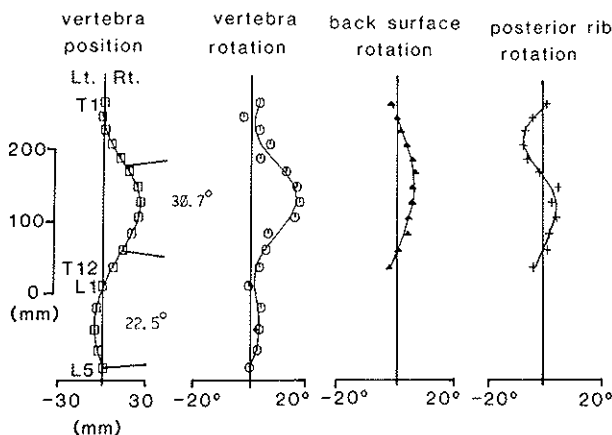


FIG. 4. Graphs of measurements from a patient with a right thoracic scoliosis. The first graph shows each vertebra position in the posteroanterior plane, with a magnified horizontal axis. On this graph, the computer generated Cobb angles and end vertebrae of curves are marked, along with the identifications of T1, T12, L1, and L5. The other three graphs show three components of axial rotation measured at each anatomic level on the horizontal axis, with elevation of the corresponding vertebra on the vertical axis.

TABLE 1. Pearson correlation coefficients from linear regression analysis of maximum values of each measurement in each curve

	Vertebra rotation	Rotation of plane of maximum curvature	Back surface rotation	Posterior rib rotation
Cobb angle	0.77	-0.71	0.88	0.63
Vertebra rotation		-0.56	0.77	0.63
Rotation of plane of maximum curvature			-0.69	-0.48
Posterior rib rotation				0.65

DISCUSSION

This study has confirmed that there are many components to the rotation of the trunk in scoliosis, and measurements of the axial rotational components differ from each other. There was large variability in the relationship between the Cobb angle and the rotation of the plane of maximum curvature. This mainly resulted from the large variability in the degree of curvature in the sagittal plane among these patients, ranging from 5° of lordosis to 35° of kyphosis in the part of the spine bounded by the end vertebrae of a scoliosis. The vertebra rotation at the curve apex was in an opposite direction to the rotation of the plane of maximum rotation for kyphotic curves, which formed the majority of the curves studied here. The vertebra rotation at the curve apex was less in magnitude than the rotation of the plane of maximum curvature. Therefore, the scoliosis deformity should not be considered as an "en bloc" rotation of the segment of the spine bounded by the end vertebrae.

The rotation of the plane of maximum curvature of the spine is dependent on which part or region of the spine is used to define this rotation. Here, the part of the spine bounded by the end vertebrae of the scoliosis curve (21) was used. Dickson et al. (10) have proposed that a scoliosis always occurs in combination with a lordotic region of the spine, in which case the direction of rotation of both the plane of maximum curvature and of the apical vertebra would be in the same direction, although the two rotations would not necessarily be of the same magnitude. With the definition of sagittal plane curvature used here, and since this study was directed at curves in the thoracic region only, the majority of the curves were found in a kyphotic spinal region. The rotation of the plane of maximum curvature was measured according to the principles given by Peloux (16) and by Raso (18), using the end vertebrae (21) to define the limits of the curve. Other definitions of auxiliary spinal curvatures were not examined here.

There was a strong statistical trend of the verte-

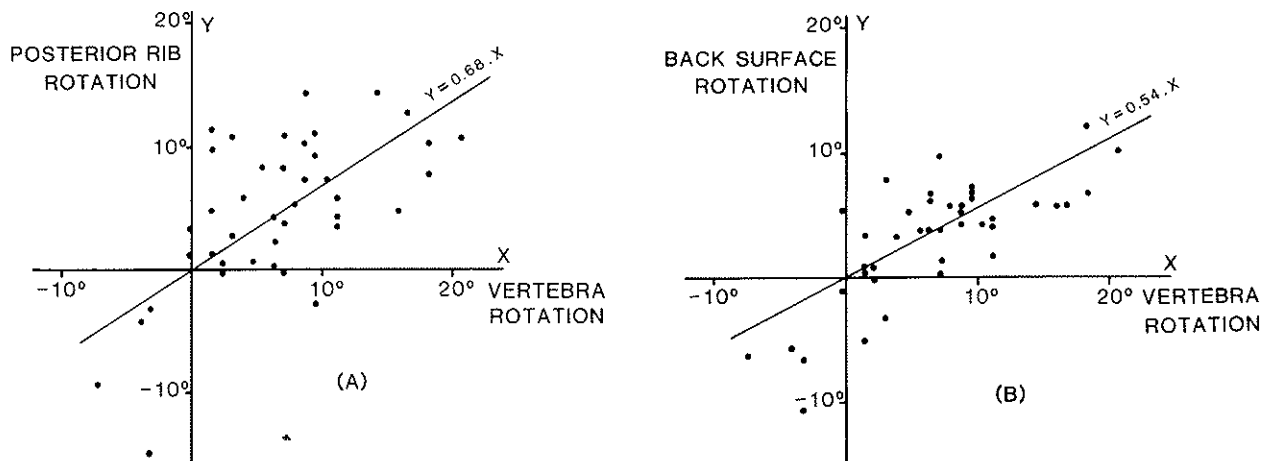


FIG. 5. Scatterplots showing relationships between the three components of thoracic rotation (maximum values from each curve, regression lines, and regression equations were calculated after elimination of the statistically insignificant constant (intercept) term. (A) Posterior rib rotation and vertebra rotation. (B) Back surface rotation and vertebra rotation.

bra rotation being greater than the corresponding back surface rotation in these patients. It was expected that the rotation of the ribs would correspond more closely to that of the back surface than that of the associated vertebra. It was therefore surprising that the posterior rib rotation had a magnitude generally intermediate between that of the vertebra rotation and of the back surface rotation. Since the back surface rotation is generally less in magnitude than both the vertebra rotation and the posterior rib rotation, it appears that the scapulae and the overlying soft tissues partially obscure the skeletal asymmetry as seen at the back surface.

The mechanism that produces axial rotation of the vertebrae in scoliosis is still unclear. Lovett (14) and Arkin (2) believed that lateral bending of the spine and axial rotation were inherently connected with each other, to an extent determined by the degree of flexion or extension. The observation of "coupling" between lateral bending and axial rotation in intervertebral joints has led to the suggestion that it is this kinematic property of the spine that leads to the axial rotation in scoliosis. However, the observation that the relative axial rotation between vertebrae is in opposite senses in the upper and lower parts of a scoliosis curve, but that the direction of relative lateral rotation is constant, implies that this mechanism alone cannot be responsible.

The "lordosis" theory, which proposes that abnormal spinal curvature predisposes to lateral curvature in combination with axial rotation (7,8,10,22), is supported by experimental evidence from isolated spinal specimens (13) and by animal studies (7,22), but apparently requires that the lordosis be constrained asymmetrically or be accompanied by an initial frontal plane asymmetry. This present cross-sectional study does not address the question of initiation of the deformity, but the results have some implications for the mechanism of progression of thoracic scoliosis. Since the amount of axial rotation in relationship to lateral curvature is very similar in curves in both lumbar and thoracic regions (25), the deformity of the rib cage is required either to guide or to permit the axial rotation of the vertebrae in the curve. If the ribs were to retain their shape rigidly, then rotation at the costochondral region and costovertebral articulations would occur as the vertebrae deviated laterally. Since the separation between each pair of rib ends is greater anteriorly than at the posterior ends, such a rigid linkage would involve vertebral rotation in the same sense as that seen in thoracic scolioses, and would

produce a "rib hump" on the convex side. In reality, some deformation of the ribs' curvature occurs, together with asymmetrical lateral tilting ("bucket handle" rotation) of the ribs, so this process of progression must involve a complex interaction of articulation and deformation of the rib cage in three dimensions.

Acknowledgment: This work was supported by NIH ROI AR 38507. This study was performed with the assistance of Morey S. Moreland, M.D., Lise MacDonald, R.T., and Jean Dansereau, Ph.D.

REFERENCES

1. Andriacchi T, Schultz AB, Belytschko T, Galante J: A model for studies of mechanical interactions between the human spine and rib cage. *J Biomech* 7:497-507, 1974
2. Arkin A: The mechanism of rotation in combination with lateral deviation in the normal spine. *J Bone Joint Surg [Am]* 32:180-188, 1950
3. Armstrong GWD, Livermore NB, Suzuki N, Armstrong JG: Nonstandard vertebral rotation in scoliosis screening patients. Its prevalence and relation to the clinical deformity. *Spine* 7:50-54, 1982
4. Benson DR, DeWald RL, Schultz AB: Harrington rod distraction instrumentation. Its effect on vertebral rotation and thoracic compensation. *Clin Orthop* 125:40-44, 1977
5. Bunnell WP: An objective criterion for scoliosis screening. *J Bone Joint Surg [Am]* 66:1381-1387, 1984
6. Dansereau J, Stokes IAF: Radiographic reconstruction of 3-D human rib cage. *J Biocheck* 21:893-901, 1988
7. Deacon P, Flood BM, Dickson RA: Idiopathic scoliosis in three dimensions: a radiographic and morphometric analysis. *J Bone Joint Surg [Br]* 66:509-512, 1984
8. Deane G, Duthie RB: A new projectional look at articulated scoliotic spines. *Acta Orthop Scand* 44:351-365, 1973
9. DeSmet AA, Tarlton MA, Cook LT, Berridge AS, Asher MA: The top view for analysis of scoliosis progression. *Radiology* 147:369-372, 1983
10. Dickson RA, Lawton JO, Archer IA, Butt WP: The pathogenesis of idiopathic scoliosis. Biplanar spinal asymmetry. *J Bone Joint Surg [Br]* 66:8-15, 1984
11. Gaines RW, McKinley LM, Leatherman KD: Effects of the Harrington compression system on the correction of the rib hump in spinal instrumentation for idiopathic scoliosis. *Spine* 6:489-493, 1981
12. Götze HG: Der Rotationsindex bei idiopathischen Thorakalskoliosen. *Z Orthop* 111:737-743, 1973
13. Jarvis JG, Ashman RB, Johnston CE, Herring JA: The posterior tether in scoliosis. *Clin Orthop* 227:126-134, 1988
14. Lovett RW: The mechanism of the normal spine and its relation to scoliosis. *Boston Med Surg J* 153:349-358, 1905
15. Panjabi MM, Brand RA, White AA: Mechanical properties of the human thoracic spine as shown by three-dimensional load-displacement curves. *J Bone Joint Surg [Am]* 58:642-652, 1976
16. Peloux J du, Fauchet R, Faucon B, Stagnara P: Le plan d'élection pour l'examen radiologique des cyphoscolioses. *Rev Chir Orthop* 51:517-524, 1965
17. Perdrille R, Vidal J: Étude de la courbure scoliotique.

- L'importance de l'extension et de la rotation vertébrale. *Rev Chir Orthop* 67:25-34, 1981
18. Raso J, Gillespie R, McNeice G: Determination of the plane of maximum deformity in idiopathic scoliosis. *Orthop Trans* 4:23, 1980
 19. Roaf R: Rotation movement of the spine with special reference to scoliosis. *J Bone Joint Surg [Br]* 40:312-332, 1958
 20. Schultz AB, Galante JO: A mathematical model for the study of mechanics of the human vertebral column. *J Biomech* 3:405-416, 1970
 21. Scoliosis Research Society, Terminology Committee: A glossary of scoliosis terms. *Spine* 1:57-58, 1976
 22. Somerville EW: Rotational lordosis: the development of the single curve. *J Bone Joint Surg [Br]* 34:421-427, 1952
 23. Stokes IAF, Armstrong JG, Moreland MS: Spinal deformity and back surface asymmetry in idiopathic scoliosis. *J Orthop Res* 6:129-137, 1988
 24. Stokes IAF, Bigalow LC, Moreland MS: Measurement of axial rotation of vertebrae in scoliosis. *Spine* 11:213-218, 1986
 25. Stokes IAF, Bigalow LC, Moreland MS: Three-dimensional spinal curvature in idiopathic scoliosis. *J Orthop Res* 5:102-113, 1987
 26. Stokes IAF, Moreland MS: Measurement of the shape of the surface of the back in patients with scoliosis. The standing and forward bend positions. *J Bone Joint Surg [Am]* 69:203-211, 1987
 27. Stokes IAF, Shuma-Hartswick D, Moreland MS: Spine and back shape changes in scoliosis. *Acta Orthop Scand* 59:128-133, 1988
 28. Thulbourne T, Gillespie R: The rib hump in idiopathic scoliosis. Measurement, analysis and response to treatment. *J Bone Joint Surg [Br]* 58:64-71, 1976
 29. White AA: Kinematics of the normal spine as related to scoliosis. *J Biomech* 4:405-411, 1971