

Three-Dimensional Spinal Curvature in Idiopathic Scoliosis

Ian A. F. Stokes, Llynda C. Bigalow, and Morey S. Moreland

University of Vermont, Department of Orthopaedics and Rehabilitation, Burlington, Vermont, U.S.A.

Summary: Scoliosis is usually considered as a deformity of the spine in the frontal plane, without reference to curvatures in other planes. In this study, the three-dimensional shape of the spine of 104 patients with untreated idiopathic scoliosis (5–55° Cobb) was studied by means of stereo radiographs to determine relationships between curvature of the spine in the frontal plane view, in the lateral view, and in the intermediate views. There was a weak but statistically significant correlation ($r = 0.2$) relating greater scoliosis with lesser kyphosis or greater lordosis. In the thoracic region, the sagittal plane spinal curvature was less than that measured in a population without scoliosis (mean difference, $7.72 \pm 9.9^\circ$). Seventy-four of 76 scolioses in the upper region of the spine with lateral curvature greater than 5° Cobb were kyphotic. Sixty-four of 84 curves greater than 5° Cobb in the lower region were lordotic. Measuring curvatures in the plane of symmetry of the rotated apical vertebra altered these ratios to 69 of 76 kyphotic in the upper region and 68 of 84 lordotic in the lower region. The plane of maximum curvature of sections of the spine with scoliosis was not related to the plane of symmetry of the rotated apical vertebra, for in kyphotic regions of the spine the rotations of these two planes were in opposite directions. In all cases, the magnitudes of the rotations were quite different, i.e., by a factor of -0.22 for curves in thoracic region and by a factor of 0.24 for curves in the lumbar region. This implies that mechanical measures to correct this spinal deformity or to prevent progression should apply different rotations to the apex from those applied to the curve as a whole and, in opposite senses, in curves in kyphotic regions. There was no evidence of an abnormality of sagittal curvature of a magnitude to implicate it in the etiology or in the treatment. **Key Words:** Scoliosis—Stereoradiography—Spine—Spinal curvature—Vertebral rotation.

The constraint of conventional radiography leads to the concept of scoliosis as a lateral curvature of the spine, viewed in the frontal or coronal plane projection. This paper is a report of the use of stereoradiography in 104 patients with idiopathic scoliosis analyzed with the help of computerized graphic display and measurement of the spine shape. With two radiographic images of the spine it was possible to view and to analyze the spine's shape in any plane, including the sagittal plane, the postero-anterior (PA) plane, the plane of maximum

curvature (the plane of best fit to the three-dimensional curved form of the spine), and the plane rotated by the amount of the axial rotation of the apex vertebra in the curve.

The possibility of interaction between curves in the spine with scoliosis has long been recognized. Adams (1) wrote about the obliteration of the natural sagittal curves in the spine in cases of scoliosis, such that the spine was flattened in the dorsal and lumbar regions. He described a case of a preserved spine with a severe scoliosis having a reversed curvature in the thoracic region. He also noted that rotation of the vertebrae and their spinous processes could exaggerate this effect on the back surface. Deacon et al. (5) recently described this flattening

Address correspondence and reprint requests to Dr. I. A. F. Stokes at University of Vermont, Department of Orthopaedics and Rehabilitation, Burlington, VT 05405, U.S.A.

or reversal of the kyphosis in a study of a series of 11 anatomical specimens with scoliosis. Dickson et al. (9) repeated the earlier work of Somerville (18) in which a lordosis was produced in the spines of growing rabbits by surgical wiring of the spinous processes. In some cases, this produced a spine also having lateral curvature. Dickson et al. (9) drew attention to the appearance of the spine in the view in which the apex vertebra is viewed from the side. In this projection, the spine with scoliosis was more lordotic or less kyphotic. Deane and Duthie (6) found reduced posterior heights of the vertebral bodies at the apex of both thoracic and lumbar scolioses in five spines with severe scoliosis compared with three normal spines. However, if the developing scoliosis were responsible for the obliteration of the kyphosis in the sagittal plane curve, one would expect to see a negative correlation between the amount of scoliosis and the amount of kyphosis in the thoracic region. DeSmet et al. (8) reported a series of 31 cases of patients with right thoracic idiopathic scoliosis studied by means of stereoradiography in which there was no significant correlation between the amount of scoliosis and the amount of kyphosis. This was true for two definitions of kyphosis, first with kyphosis measured in the conventional manner over the parts of the spine between inflection points of zero curvature seen in the lateral projection of the spine and, second, by measuring the amount of curvature over the same region of the spine as was found to contain the scoliosis seen in the antero-posterior (AP) view. Additionally, there was no strong evidence of these patients having abnormally reduced kyphosis (as might be seen if reduced kyphosis were a pre-existing abnormality as opposed to one that develops along with the scoliosis).

By means of computer graphics it is possible to rotate an image of the spine into any view to find curvatures in that projection (Fig. 1). Raso et al. (14) and others have described a plane of maximum curvature in the spine with scoliosis. In the normal spine the greatest curvature is in the midsagittal or medial plane, whereas in scoliosis the plane of maximum curvature is rotated and makes an angle with the sagittal plane. Raso (14) reported (in 17 cases) that this angle was comparable with the magnitude of the Cobb angle. Thus, for example, in a spine with a scoliosis measuring 30° Cobb, the plane of best fit (the plane transecting the greatest number of vertebrae in the curve) could be rotated about 30° to the sagittal plane or about 60° from the

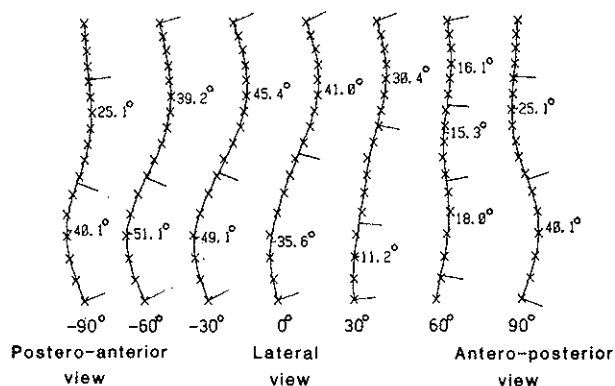


FIG. 1. Views of a spine shape reconstructed from stereo radiographs with help of a computer. In each view, each cross represents the position of a vertebral body center. The views are of the spine of a 16-year-old patient with scoliosis (seen in the antero-posterior view) measuring 21.5° and 42.1° Cobb. The other views were obtained by rotating the three-dimensional image in 30° increments from the left lateral view to the right lateral view. In each view, the curvatures were found by the computer algorithm that first located apices and inflection points as described in the text.

coronal plane. Peloux et al. (15) defined a preferred plane of projection as one cutting through the apical vertebra and the two end vertebrae of the curve. DeSmet et al. (7) adopted a similar approach to the display of scoliosis deformity when he used computer graphics to show an overhead plan view of spines with scoliosis and how they changed over time. These views showed the deviation of the vertebrae from the vertical axis in both the lateral and sagittal directions. Perdriolle and Vidal (16) also stressed the apical view as that which shows the vertebral rotation. They favored frontal and lateral radiographic views of the spine rotated from the anatomical planes by the amount of the vertebral rotation. In adopting these views, Perdriolle and Vidal (16) found that the amount of apparent kyphosis could be altered or even reversed, and they introduced the term "paradoxical kyphosis" to describe this. Dickson et al. (9) reported a similar observation in adolescent idiopathic scoliosis.

Clinically, recognition of the three-dimensional nature of the deformity can lead to more effective treatment through better definitions of the true deformity, and may also give insight into the mechanism of the progression of the deformity. In this study, patients with idiopathic scoliosis were studied radiographically to examine: (1) whether increased degrees of scoliosis were associated with increased or decreased curvature in the sagittal plane; (2) whether the curvature in the sagittal

plane was greater or less than the published curvature measurements of lateral radiographs of a group of subjects without scoliosis in the age range 20–29 years; and (3) the relationships between curvatures in the coronal plane, the sagittal plane, the plane of maximum curvature, and the plane of the most axially-rotated vertebra.

METHODS

Patients Studied

One hundred and four patients with adolescent onset idiopathic scoliosis greater than 5° Cobb were studied by means of low-dose stereoradiography. These patients were attending a scoliosis clinic. At the time of study, none of them had undergone treatment. There were sixteen males and 88 females. The mean age was 14.95 years (range, 8.3–40 years). Details of the scoliosis curvatures are given in Table 1.

For ethical reasons, no children without scoliosis were radiographed. Values of the sagittal curvature between pairs of vertebrae in spines of young adults with no known pathology were published by Stagnara et al. (19), and these were used in comparisons with our group. The age range of Stagnara et al.'s group was 20–29 years (43 women, 57 men), with no significant differences in the measurements between men and women.

Some adjustments to the measurements of Stagnara et al. (19) were necessary to make them comparable with our measurements of spinal curvature. This required measurements of the vertebral wedging (seen in the lateral view) as described later in this paper. These measurements of vertebral shape were taken from lateral films of a separate population of 44 patients radiographed for problems unrelated to spinal deformity. The age range of these subjects was 11.5–41 years, mean 22.5 years. There were 29 males and 15 females.

Stereoradiography and Three-Dimensional Measurements

The spinal shape was measured radiographically by marking anatomical "landmarks" on the images of the vertebrae (from T1 to L5) for digitization and computerized geometric analysis. In this technique, two films of each patient were made, one in a PA projection and one 15° oblique view (Fig. 2). Radiographs were made with 36-inch films so as to cover the entire length of the spine. This procedure involved the making of one extra x-ray film beyond the clinical PA film, and was offered to patients as a voluntary procedure with informed consent. An extremely low-dose technique [modified from that of Ardran et al. (2)] was used to provide a skin entry dose of between 15 and 20 mRem (depending upon the size of the patient). This skin entry dose was comparable with 1 month of background whole-body radiation.

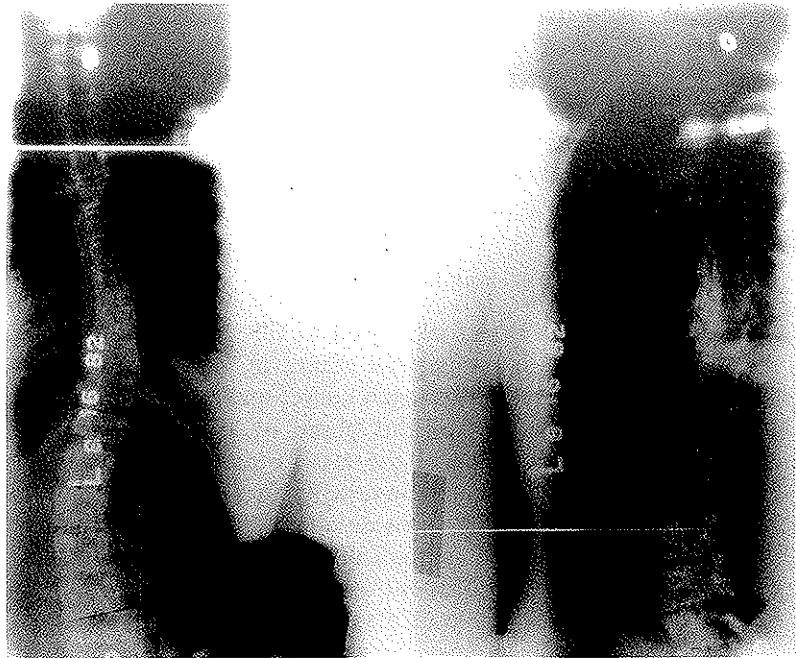The position of each vertebral landmark in space was calculated from its image position in the two radiographic image planes by a photogrammetric method based on the Direct Linear Transformation technique of Marzan (12). This technique uses a computer program that combines measurements of the positions of images in the two film planes to calculate the position of the point that made the image. This was done after the geometry of the tube positions and film planes was calibrated. Calibration of the stereophotogrammetric setup and computer program was done with films of a calibration object of known dimensions (20).

Six image points (anatomic landmarks) on each vertebra were measured and reconstructed. These landmarks were the endplate centers and the upper and lower margins of each pedicle base (Fig. 3). The endplate centers were then used to find the three-dimensional position of the center of each vertebra centrum (the midpoint between the endplate centers) and the axial rotation of each vertebra [by the method of Stokes et al. (21)]. The

TABLE 1. Measurements of the coronal plane curvatures in 104 patients with idiopathic scoliosis (based on a postero-anterior film projection)

| | Number | | Cobb angle | | |
|--------------------------------------|--------------|-------------|------------|--------------------|-----------|
| | Right convex | Left convex | Mean | Standard deviation | Range |
| Upper region (76 curves) T1-T9 apex | 50 | 26 | 21.7° | 13.1° | 5.4–60° |
| Lower region (84 curves) T10-L5 apex | 26 | 58 | 21.3° | 14.68° | 5.0–60.8° |

FIG. 2. Stereoradiographic pair of a patient with scoliosis. These are the views used to reconstruct the spine shape shown in Fig. 1. The standard postero-anterior view (*left*) was used clinically. The additional view (*right*) to make the stereo pair was made with an additional ray tube angled at 15° to the postero-anterior direction.



centrum points were then used to calculate spinal curvatures in various planes. The accuracy of the determination of landmarks was primarily dependent upon the accuracy with which they were identified on each film. In a study with two observers remarking sixteen vertebrae on each of four typical films after erasing all marks, the standard deviation of the calculated three-dimensional coordinates was 1.47 mm in the vertical direction, 0.88 mm in the horizontal direction (coronal plane), and 3.8 mm in the horizontal direction (sagittal plane). These random errors produced errors in the determination of sagittal and frontal plane curvatures that were small compared with variability due to possible postural changes in the patient, as data were smoothed prior to curve identification. As measurements were made of intrinsic spinal shape, the exact position of the patient relative to the film plane was not important. The axial rotation of vertebrae was determined with a standard deviation of $\pm 3.6^\circ$ (21).

Number of Curves in Each Patient

In general, measurements were obtained for two scoliotic regions in each spine. However, forty-eight patients were designated as having only a single curve. This was done if they only had one curve (as viewed in the frontal plane) with a Cobb

angle greater than 5° , or if the largest curve was at least 10° greater than all others in the same patient. This objective method for accepting curves into the study was selected because it gave a close agreement with those curves previously determined as clinically significant on the basis of magnitude and degree of axial rotation. For this study, we categorized curves as being in one of two regions (upper and lower) to facilitate comparisons with kyphosis

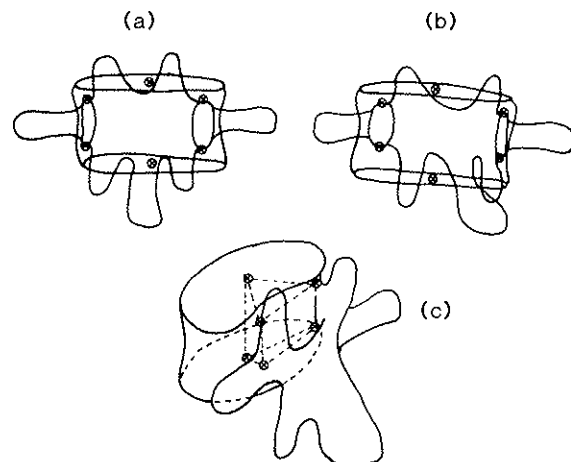


FIG. 3. Positions of six landmarks (endplate centers and bases of pedicles). **a:** Postero-anterior view traced from a radiograph **b:** Oblique radiograph tracing. **c:** Diagrammatic view of the spatial orientation after stereophotogrammetric reconstruction.

and lordosis measures. "Lower" curves (84 in number) were those with an apex below T9; "upper" curves were those with an apex at or above T9 (76 curves). If more than one curve in a given region was identified, only the larger was considered in the analyses.

Measurements of Spinal Curvatures

The spinal curvature was measured in the coronal (frontal) plane, in the sagittal plane, in the plane of maximum curvature of each curve, and in a plane rotated from the sagittal plane by the amount of the axial rotation of the most rotated vertebra in each curve. Thus, measurements of each curve were made in four separate planes. Two of the planes were standard anatomical planes, and the other two were rotated about a vertical axis from these planes. The plane of maximum curvature was found for each scoliosis curve identified in the coronal plane. It was found mathematically by rotating the three-dimensional image of the spine in 2.5° increments until the curvature (measured by the "constrained" method defined below) reached a maximum value. The amount of this rotation of the plane of maximum curvature from the anatomical planes was also noted.

The curvature was measured by automated mathematical techniques using a computer. The method is illustrated in Fig. 4. The method could be used with the spine projected onto any plane, as shown

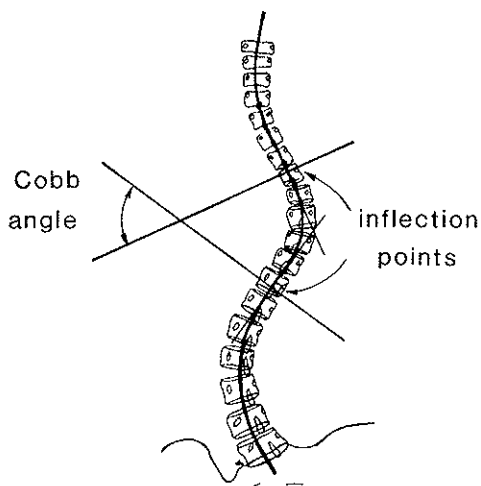


FIG. 4. Method for determining curvature of the spine by the Cobb method adapted to an analytic method programmed in the computer.

in Fig. 1. First, a smooth line was fitted mathematically through the images of the centers of the vertebral bodies, using Fourier analysis with five sine waves added together to represent the spine shape. The "fundamental" sine wave had a period equal to the length of the spine image. This fundamental together with four harmonics of the fundamental were found to give adequate representation of the spine shape. Subsequently, apices and inflection points were located mathematically. An "apex" was at a point of maximal lateral deviation from the spinal axis, and an "inflection point" was at a point of zero curvature.

For each apex, a "computer Cobb angle" was measured as the angle between the normals to the curves at the corresponding inflection points. This method of automatic calculation of Cobb angles was similar to that described by Jeffries et al. (10). The correlation of such curvatures in the frontal plane with clinical Cobb angles (4) measured conventionally from PA x-ray films was close ($r = 0.97$), with a regression equation formulated as: clinical measurement = $(0.88 \pm 0.009) \times$ computer measurement. Thus, the computer tended to overestimate the Cobb angle by about 12% compared to clinical measurement. This was attributed to its finding inflection points that did not necessarily coincide with the vertebral endplates used in clinical measurement and thereby maximizing the Cobb angle measurement. The two measurements agreed, on average, on the level of the apex and end vertebrae of the 160 curves, but with a discrepancy of up to four vertebrae (in one case) on the apex level, and up to six vertebrae (in one long, small curve) on the end vertebra of the curve.

Curvatures in the lateral and intermediate views were measured by three methods that were designated unconstrained, constrained, and apical curvature. The "unconstrained" measure was obtained by the automated computerized method for measuring Cobb angle. Inflection points of the curve in that particular view of the spine were found, and the angle between normals to the curve at adjacent inflection points was measured in degrees. In the PA (coronal) view that was the conventional Cobb angle. The "constrained" measure was of the angle in degrees between perpendiculars to the curve at those anatomical levels where inflection points had been found in the PA (coronal) view. Thus, in any view of the spine, this "constrained" measure was of the curvature referred (or constrained) to that part of the spine that had been

identified as the region of the scoliosis (by the Cobb method) in the frontal view (see Fig. 5).

“Apical” curvature was measured at the region of the curve where an apex had been found in the coronal plane. It was measured as the quotient of the radius of curvature of the spine projected into any particular plane. The units of measurement were therefore in millimeters⁻¹. This is the conventional mathematical measurement of curvature. It was used in this study because it could be used to measure the curvature locally at the apex of a curve rather than over the entire length of the curve.

In this study, it was necessary to distinguish between left and right convex curves, lordosis and kyphosis, and clockwise and counter-clockwise axial rotations. Thus, a sign convention was adopted for this study so that a left convex scoliosis had a negative Cobb angle whereas a right curve was measured with a positive Cobb angle. Similarly, a sagittal plane curvature that was kyphotic was positive, while a lordotic one was negative. Rotations (of the apical vertebra and of the plane of maximum curvature) were measured from an origin in the sagittal plane. Rotations that were clockwise as seen from above were measured as positive and counterclockwise rotations from the sagittal plane curve negative.

Sagittal Curvature in Normal Spines and in Patients With Scoliosis

The sagittal plane curvature measured in the study patients was compared with that measured previously by Stagnara et al. (19). Stagnara measured the sagittal curvature between each pair of vertebrae from T4 to L5 in lateral radiographs of these subjects. First, adjustments to the measurements of Stagnara et al. were made so that they were comparable with measurements made in this study. These were necessary because the published measurements had been made from lateral radiographs by the conventional method of drawing lines through the endplate images. Patients with scoliosis studied here, however, did not all have lateral radiographs, and the curvature in the lateral projection was measured by means of perpendiculars to the mathematical curve fitted through the measured positions of the vertebral centra. Because of vertebral wedging, the endplates are not always parallel to the perpendicular to the curve. Therefore, lateral radiographs of 16 thoracic spines and 28 lumbar spines taken for reasons not related to spinal deformity were studied by both methods to provide mean values of these differences due to vertebral wedging. These corrections were applied to the

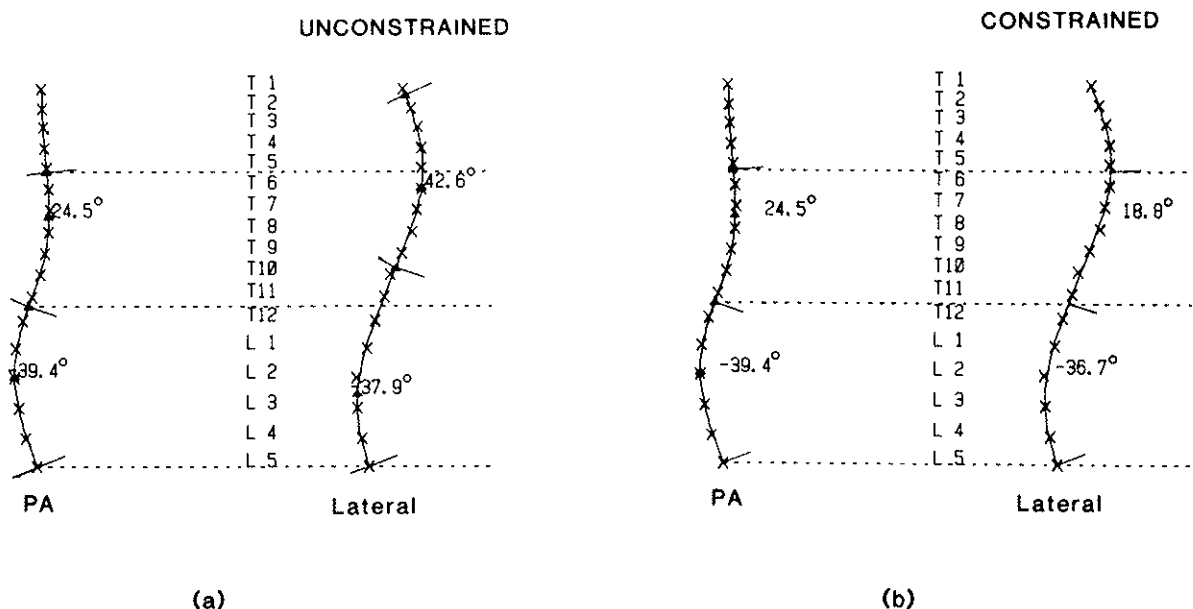


FIG. 5. Definition of the (a) “unconstrained” and (b) “constrained” measures of curvature in the spine in the lateral view. The same principles were applied to finding these two measurements of curvature for intermediate views of the spine. The unconstrained measurement was obtained by finding the angle between normals to the curve at inflection points. The constrained measurement was obtained by measuring the angle between normals to the curve at the same anatomical levels where inflection points were found in the postero-anterior view (the clinical limits of the curve).

mean angles of lateral curvature of the spine measured by Stagnara et al. (19) before comparison with the patients with scoliosis (Table 2).

Sagittal plane curvatures in the spines of patients with scoliosis were measured for comparison with these "normal" curvatures. The measurements were made between the conventionally-used end vertebrae (T5 to T12, L1 to L5), between inflection points in the sagittal plane view of the patient's spine, and between those vertebrae that were found in the coronal view of the spine as the end vertebrae of a scoliosis. In the latter two cases, if the upper-end vertebra of a curve was above T4, the measurements were made from the T4 level instead of the actual end vertebra to facilitate comparisons with the normative measures of Stagnara et al. (19), which were not made above that level.

Regression Analysis

Linear regression analysis was used to find relationships between measured variables. "Least squares" fitting of a line to experimental data was used. The degree of correlation was measured by the Pearson correlation coefficient (r), and statisti-

TABLE 2. Differences between measurements of curvature of the spine in the lateral projection according to the methods of using lines drawn across endplate images and using lines drawn perpendicular to a curve drawn through the vertebral body centers

| Vertebral body | Number of patients studied | Add to upper vertebra | Add to lower vertebra |
|----------------|----------------------------|-----------------------|-----------------------|
| T4 | 4 | 1.33 | -1.23 |
| T5 | 16 | -2.08 | 2.15 |
| T6 | 16 | -4.30 | 0.61 |
| T7 | 16 | -4.41 | 0.09 |
| T8 | 16 | -1.77 | 2.42 |
| T9 | 17 | -3.49 | 2.70 |
| T10 | 19 | -3.84 | 1.76 |
| T11 | 22 | -2.05 | 4.99 |
| T12 | 24 | -4.32 | 10.46 |
| L1 | 29 | -3.76 | 10.30 |
| L2 | 29 | 0.67 | 11.77 |
| L3 | 28 | 2.21 | 11.66 |
| L4 | 28 | 7.10 | 18.32 |
| L5 | 28 | 1.09 | 5.56 |

The differences between the two methods are due to vertebral body wedging in the lateral projection. The values in this table were used to permit comparisons between measurements reported by Stagnara et al. (19), who employed the endplate-image method, and measurements made of patients in this study (where the vertebral body center method was used). The convention used was that positive values of sagittal curvature correspond to kyphosis and negative values correspond to lordosis.

cally significant relationships were described by a linear regression equation of the form $y = a + bx$, where y signified a dependent variable, x the independent variable, and a and b were constants. The statistical significance of such relationships was assessed by analysis of variance. In many cases of relationships between pairs of measurements of spinal asymmetry, the constant term a was not significant, in which case equations were recalculated in the form $y = bx$, where b was the regression coefficient, expressing the factorial relationship between the dependent and independent variables. Such relationships without a constant term reflected regression equations passing through the origin of axes, and gave the ratio of the mean values of the dependent and independent variables.

Because we adopted a sign convention in this study by which left curves were assigned negative Cobb angles, right curves positive Cobb angles, etc., the spread of numerical values in the regression analyses was approximately doubled compared with the spread of absolute values. Regression analysis using absolute values would be inappropriate in this study, as it would result in all data being represented graphically in the first quadrant. By adopting a sign convention, we permitted data to fall into any of the four quadrants of the axis system used in regression analysis.

RESULTS

Curvatures in the Sagittal and Coronal Planes

Correlation analysis was performed separately for the upper and lower curve regions to find whether the amount of sagittal plane curvature (kyphosis or lordosis) was related to the absolute value of the Cobb angle. Two measures of sagittal plane curvature (constrained and unconstrained to the coronal plane curves) were examined. There was a tendency for increasing Cobb angles to be related to increased lordosis or decreased kyphosis. A correlation of $r = -0.22$ ($p = 0.03$) was found in the upper curve region between Cobb angle and "constrained sagittal curvature." In the lower curve region there was a correlation coefficient ($r = -0.2$, $p = 0.03$) between Cobb angle and "unconstrained sagittal curvature." These correlations represent a weak association of lesser kyphosis (or increased lordosis) with increasing scoliosis. The degree of scoliosis explained about 5% of the variability in sagittal plane curvature, based on the R^2 value.

Comparison between sagittal plane curvatures in the patients with scoliosis and the Stagnara et al. (19) measurements (corrected as indicated in Table 2) indicated that the patients had reduced kyphosis compared with the normal group in the upper curve region where the difference was $-7.72 \pm 9.92^\circ$ (mean and standard deviation of 76 curves) for the constrained measure of sagittal plane curvature and $-5.88 \pm 10.84^\circ$ for the unconstrained measure. Both of these differences were highly significantly different from zero ($p < 0.001$). Only fifteen of the curves were more kyphotic than the mean value reported by Stagnara et al., whereas 61 were less kyphotic than the corresponding mean value based on the constrained measure. In the lower curve region, the mean difference in sagittal plane curvature from the corresponding values given by Stagnara et al. was less than 2° by both constrained and unconstrained measures, which was not significant ($p = 0.2$). In the lower region of the spine, 46 curves were more lordotic and 38 were less lordotic than the value given by Stagnara et al. using the constrained measure.

In the lower curve region, 54 of 86 curves were in a lordotic (negative curvature) region according to the apical measurement of sagittal plane curvature. The remaining 32 curves had positive apical curvature in the sagittal plane. In the upper curve region, 67 patients had positive (kyphotic) curvature in the sagittal plane at the curve apex. Nine patients had negative curvature at the curve apex when viewed in the sagittal plane. However, only two patients had lordosis in the upper curve region by the constrained measurement.

Plane of Maximum Curvature and Plane of Most Rotated Vertebra

The plane of maximum curvature in the upper curve region was rotated counter-clockwise (see from above) from the sagittal plane in all cases of right convex curves, as all these curves occurred in a kyphotic part of the spine as defined by the constrained and unconstrained measures of lateral curvature (Fig. 6). The converse occurred for left convex curves in this region. The amount of the rotation of this plane correlated with the degree of scoliosis (as expected) with a coefficient of correlation $r = -0.8$ for the case of the rotated constrained curve and $r = -0.63$ for the unconstrained curve ($p < 0.001$ in both cases). In the case of the

constrained curve the linear regression coefficient was -1.46 , meaning that on average, the rotation of the plane of maximum curvature was -1.46 times the frontal plane Cobb angle in degrees. For the unconstrained curve the regression coefficient was -0.8 . The curvature in the plane of maximum curvature was greater than the curvature in the sagittal plane by a mean value of 9.53° by the constrained measure in these upper region curves.

In the lower curve region, the characteristics of the plane of maximum curvature varied depending on whether the scoliosis was in a kyphotic or lordotic region of the spine as seen in the sagittal plane. Curves in a lordotic region had a plane of maximum curvature that rotated counter-clockwise

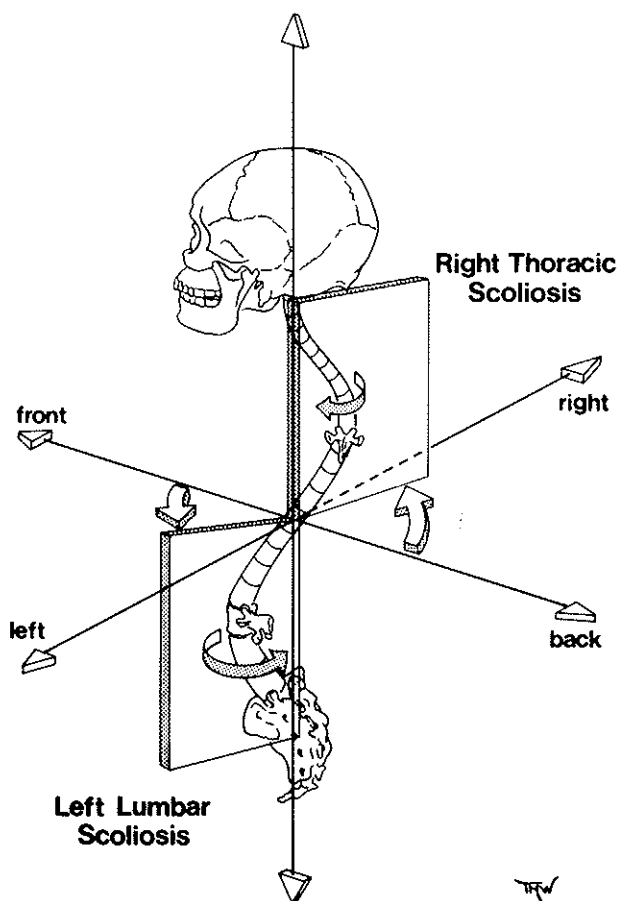


FIG. 6. View of the spine with scoliosis as if viewed from a left postero-lateral direction. The upper curve region (in a kyphotic part of the spine) has a plane of maximum curvature rotated counterclockwise from the sagittal plane, as is also the case in the lower curve region. The apex vertebra is rotated clockwise in the upper curve and counterclockwise in the lower curve. Thus, the two rotations are in the same direction in the lumbar region and in opposite senses in the upper region.

(as seen from above) in cases of a left convex scoliosis (Fig. 6) and clockwise for right convex curves in a lordotic region. Similarly, the rotation was clockwise for the left convex curves occurring in a kyphotic region and vice versa (as was also seen in the upper curve region). The amount of rotation of the plane of maximum curvature from the sagittal plane correlated with the frontal plane Cobb angle ($r = 0.64$, $p < 0.001$) for constrained curves and $r = 0.29$ ($p < 0.02$) for unconstrained curves. The linear regression coefficient for the correlation in the constrained curves was 1.27, indicating rotation of this plane by an amount that was on average 1.27 times the Cobb angle in degrees. The relatively low correlation between the Cobb angle and the plane of maximum curvature rotation mainly resulted from the large variability in the degree of curvature in the sagittal plane among these patients. The curvature in the plane of maximum curvature was greater than the curvature in the sagittal plane by a mean value of 4.40° by the constrained measure in these lower curves.

The rotation of the apical vertebra was in the same direction as the rotation of the plane of maximum curvature for lordotic curves, but in an opposite direction for kyphotic curves (Fig. 6). In both cases, the amount of the apical vertebra rotation, measured by the pedicle effect method of Stokes et al. (21), was less than the rotation of the plane of maximum curvature. The correlations between these rotations and the frontal plane Cobb angle, and the corresponding regression coefficients of the statistically significant relationships are shown in Table 3. Note that the correlation between Cobb angle and vertebral rotation is positive in both upper and lower regions of the spine. The correlation with rotation of the plane of maximum curva-

ture was positive in the lower curve region and negative in the upper curve region.

Most curves in the upper region that were kyphotic in the sagittal (lateral) projection were also kyphotic in the plane of symmetry of the apical vertebra (74 of 76 kyphotic in the lateral projection; 69 of 76 kyphotic in the plane of the apical vertebra, according to the constrained measure; 67 of 76 and 60 of 76 by the apical curvature measure). The mean difference of curvature between that measured in the sagittal plane and that measured in the plane of the apical vertebra was 3.61° ($SD = 5.12^\circ$) by the constrained measure. Measurement of the sagittal plane curvature between the T5 upper endplate and the T12 lower endplate gave a mean kyphosis of 36.4° (range, $+4.5$ – 55°) in the population of patients. The comparable values for the population studied by Stagnara et al. (19) were 40.4° (range, 4.5 – 55°).

In the lower curve region, 64 were lordotic and 20 were kyphotic by the constrained sagittal plane measure; in the plane of the apical vertebra this ratio changed to 68 lordotic and 16 kyphotic. Using the apical curvature, 54 were lordotic and 30 kyphotic in the sagittal plane and 50 were lordotic and 34 kyphotic in the plane of the apical vertebra. The mean difference in curvature between that measured in the sagittal plane and that in the plane of the apical vertebra was 4.03° ($SD = 6.61^\circ$) by the constrained measure, for all the lower region curves. Measurement of the sagittal plane curvature between the L1 upper endplate and the L5 lower endplate gave a mean value of -32° (range, -61 – -2.3°) for the population of patients (negative values signify lordosis). The comparable values from the Stagnara et al. (19) population were -40.2° (range, -67.2 – -16.2°).

TABLE 3. Relationships in upper and lower curve regions between rotation of the apex vertebra, rotation of the plane of maximum curvature, and Cobb angle

| | Upper curves n = 76 | | Lower curves n = 84 | |
|-----------------|--|---|---|--|
| | Vertebra rotation | Rotation of PMC | Vertebra rotation | Rotation of PMC |
| Cobb angle | $r = 0.66$ Rotation = $0.33 \times$ Cobb | $r = -0.8$ PMC = $-1.46 \times$ Cobb | $r = 0.81$ Rotation = $0.31 \times$ Cobb | $r = 0.64$ PMC = $1.27 \times$ Cobb |
| Rotation of PMC | $r = -0.61$ Rotation = $-0.22 \times$ PMC | | $r = 0.13$ (NS) Rotation = $0.24 \times$ PMC | |

In each case, the value of the correlation coefficient (r) is given along with the regression equation. The regression equations were constrained to give a relationship passing through the origin of axes (no constant term), since, by analysis of variance, the constant term did not contribute significantly to the predictive power of the equation.

PMC, plane of maximum curve; NS, not significant.

DISCUSSION

In this study we attempted to find inter-relationships between curvature in the coronal plane (scoliosis), in the sagittal plane, and in the intermediate planes. There is very little known about the three-dimensional nature of the scoliosis deformity, as opposed to its description in the coronal plane as demonstrated by the PA radiograph. In this study, in both upper and lower curve regions there was a correlation linking loss of kyphosis or increase in lordosis with increasing frontal plane Cobb angle. In a smaller group of patients, DeSmet et al. (20) found no significant correlation. The association we found between Cobb angle and sagittal plane curvature is a weak one (although significant at $p < 0.05$), so it represents only a very small part of the explanation of the variability between individual patients. The variability in the normal population of Stagnara et al. (19) was also very large. It is not clear whether as the degree of scoliosis increases in any one patient there is an accompanying change in the sagittal curve. This could best be determined by a longitudinal study of progressive scoliosis. The alternative explanation is that a pre-existing abnormality of the curvature in the sagittal plane would place growing children at risk for development of scoliosis.

When comparing the amount of sagittal plane curvature (kyphosis and lordosis) of the patients with scoliosis with the normal population described by Stagnara et al. (19), we found that the patients had less than normal curvature in curvatures of the thoracic region (mean difference, 7.72° , or 19% of the mean normal kyphosis at T5-T12), but no abnormality of curvature in the lower part of the spine. Thus, in the thoracic region, our findings were in agreement with the proposal by Adams (1) that scoliosis is accompanied by loss of sagittal curvature. We did not find evidence for this in the lumbar region. Propst-Proctor and Bleck (13) also studied the sagittal plane curvature of 114 patients with scoliosis and compared these with a control group of 104 patients of similar age. They found a greater amount of lordosis in the scoliosis patients and no difference in the kyphosis. The control group studied by these authors were patients who had been radiographed to exclude scoliosis, spondylolisthesis, Scheurmann's disease, or hip or lower limb disorders, but when such was not found radiologically. The large amount of variability of spinal curvature in the normal population has com-

plicated attempts to determine whether scoliosis is associated with abnormal kyphosis or lordosis. Not all the patients with scoliosis were skeletally mature (their ages were between 8 and 40 years, mean = 15 years), but for ethical reasons they were compared with radiographic measurements of an adult (age 20-29) population. The variability in measurements of spinal curvature within both populations is probably much greater than any age-related differences.

While we found in these patients with scoliosis that the amount of thoracic kyphosis was less than normal, there was very little evidence that scoliosis curves were occurring preferentially in lordotic segments of the spine. In this study, lordotic segments were defined as those having negative curvature either by the Cobb-type measurements between end points of a curve, or by the mathematical measurement of curvature in the apical region. Additionally, we examined these curvatures both in the sagittal plane and in the plane of symmetry transecting the rotated apex vertebra. In all cases, the majority of the curves in the upper region of the spine were kyphotic and not lordotic. Dickson et al. (9), however, found a strong association between the apex of a scoliotic curve and a lordotic segment of the spine in a group of patients attending a scoliosis clinic, as well as in a series of spine specimens. This study is not in agreement with his findings. These findings do emphasize the need for a longitudinal study to determine how the spinal curvatures in different planes change during growth and progression of the scoliosis.

Curvatures were measured in two intermediate planes between the sagittal and coronal plane, these being the plane of maximum curvature of a region of the spine and the plane of symmetry transecting the rotated apical vertebra. These two intermediate planes were quite different from each other, and this finding gives strong evidence that the scoliosis deformity cannot be considered as an "en bloc" rotation of a segment of the spine. In a lordotic segment of the spine, the apical vertebra rotation and the rotation of the plane of maximum curvature were in the same direction. The rotations in a kyphotic part of the spine were in opposite directions. In addition, regression analysis demonstrated that the magnitude of the rotations of these two curves was quite different, by a factor of -0.22 and 0.24 for upper and lower regions, respectively (Table 3). In this study, curves were classified as occurring in either an upper or lower region of the

spine, divided at T9. This facilitated comparisons with the sagittal plane curvatures, as most upper curves were kyphotic and most lower curve were lordotic, although this differs from the accepted clinical classification into thoracic, thoraco-lumbar, and lumbar curves. However, the relationships found in our two regions were quite similar (or complementary) (Table 3). This implies that probably the geometric properties of curves found here are similar in all regions of the spine, independent of regional classifications.

The relationship between the frontal plane Cobb angle and the amount of rotation of the plane of maximum curvature was quite variable between individuals, especially in the lower region of the spine. Probably the major cause of the variability was the highly-variable degree of sagittal plane curvature. The rotation of the plane of maximum curvature is related to the ratio of the curvature in the sagittal plane to that in the frontal plane. It is possible that the presence of structural changes in the vertebrae (lateral wedging or distortion of the neural arch) would contribute to the rotation of this plane. Such changes are known to increase with Cobb angle. In this study, geometric changes in the vertebral shape (as opposed to measurements of position and orientation of vertebrae) were not investigated.

The mechanism that produces axial rotation of the apical vertebra is still unclear. Lovett (11) and Arkin (3) believed that lateral bending of the spine and axial rotation were inherently connected with each other, to an extent determined by the degree of flexion or extension. This concept of "coupling" between lateral bending and axial rotation has led to the belief that it is this kinematic property of the spine that leads to the axial rotation in scoliosis. However, Roaf (17) pointed out that the relative rotation between vertebrae is in opposite senses in the upper and lower parts of the spine. As one approaches the maximal rotation at the apex the rotation increases, but the direction of relative rotation is in the opposite direction in the part of the curve between the apex and the next inflection point.

It has long been recognized that it is an advantage to consider scoliosis in three dimensions. The plane of maximum curvature is attractive in this sense, but it may be dangerous as a tool for description of scoliosis in that it does not take into account the relationship of the anatomical planes of the vertebrae to this plane. The plane of symmetry transecting the rotated apical vertebra, on the other

hand, does not have this disadvantage. In the population of patients studied here, the plane of maximum curvature was close to the sagittal plane in the cases of small lateral deformity, while in cases with severe curves the plane of maximum curvature could be rotated as much as 90° from the sagittal plane. Conversely, measurements of scoliosis and lateral curvature were not altered greatly by making these measurements in the PA and lateral planes, as opposed to the planes referred to the plane of symmetry of the apex vertebra [the projection planes recommended by Perdriolle and Vidal (16) and by Dickson et al. (9)]. The mean change in curvature was only 4° when measured in the plane of the apical vertebra as opposed to the lateral plane.

The finding of considerable differences (of direction and magnitude of rotation) between the plane of maximum curvature and the plane of symmetry of the apical vertebra indicates that these two planes should not be confused with each other. It further demonstrates that the scoliosis deformity should not be considered as an "en bloc" rotation of a part of the spine. In the clinical management of these deformities, it may be an advantage to control or correct the axial rotation of the vertebrae, but this rotation is different from the rotation of the plane of the spine. The small differences seen in the sagittal plane curvature compared with that in the spines without scoliosis imply that this is not a significant factor in the etiology, and probably would normally require measures to change or control it clinically.

Acknowledgment: Supported by NIH grant RO1 AM 30235.

REFERENCES

1. Adams W: *Lectures on the Pathology and Treatment of Lateral and Other Forms of Curvature of the Spine*. London, J. Churchill & Sons, 1865, pp. 113-115
2. Ardran GM, Coates R, Dickson RA, Dixon-Brown A, Harding FM: Assessment of scoliosis in children: low dose radiographic technique. *Br J Radiol* 53:146-147, 1980
3. Arkin A: The mechanism of rotation in combination with lateral deviation in the normal spine. *J Bone Joint Surg [Am]* 32:180-188, 1950
4. Cobb JR: Outline for the study of scoliosis. *Am Acad Orthop Surg Inst Lect* 5:261-275, 1948
5. Deacon P, Flood BM, Dickson RA: Idiopathic scoliosis in three dimensions. *J Bone Joint Surg [Br]* 66:509-512, 1984
6. Deane G, Duthie RB: A new projectional look at articulated scoliotic spines. *Acta Orthop Scand* 44:351-365, 1973
7. DeSmet AA, Tarlton MA, Cook LT, Berridge AS, Asher MA: The top view for analysis of scoliosis progression. *Radiology* 147:369-372, 1983
8. DeSmet AA, Asher MA, Cook LT, Goin JE, Scheuch H,

- Orrick JM: Three dimensional analysis of right thoracic idiopathic scoliosis. *Spine* 9:377-381, 1984
9. Dickson RA, Lawton JO, Archer IA, Butt WP. The pathogenesis of idiopathic scoliosis. Biplanar spinal asymmetry. *J Bone Joint Surg [Br]* 66:8-15, 1984
 10. Jeffries BF, Tarlton M, DeSmet AA, Dwyer SJ, Brower AC: Computerized measurement and analysis of scoliosis. *Radiology* 134:381-385, 1980
 11. Lovett RW: The mechanism of the normal spine and its relation to scoliosis. *Bos Med Surg J* 153:349-358, 1905
 12. Marzan GT: *Rational design for close-range photogrammetry*. PhD Thesis, 1976, Univ. of Illinois. Ann Arbor, Xerox University Microfilms, 1979
 13. Propst-Proctor SL, Bleck EE: Radiographic determination of lordosis and kyphosis in normal and scoliotic children. *J Pediatr Orthop* 3:344-346, 1983
 14. Raso J, Gillespie R, McNeice G: Determination of the plane of maximum deformity in idiopathic scoliosis. *Orthop Trans* 4:23, 1980
 15. Peloux J du, Fauchet R, Faucon B, Stagnara P: Le plan d'election pour l'examen radiologique des cyphoscolioses. *Rev Chir Orthop* 51:517-524, 1965
 16. Perdriolle R, Vidal J: Etude de la courbure scoliotique. L'importance de l'extension et de la rotation vertebrale. *Rev Chir Orthop* 67:25-34, 1981
 17. Roaf R: Rotation movements of the spine with special reference to scoliosis. *J Bone Joint Surg [Br]* 40:312-332, 1958
 18. Somerville EW: Rotational lordosis: The development of the single curve. *J Bone Joint Surg [Br]* 34:421-427, 1952
 19. Stagnara P, Demauroy JC, Dran G, Gonon GP, Costanzo G, Dimnet J, Pasquet A: Reciprocal angulation of vertebral bodies in a sagittal plane: Approach to references for the evaluation of kyphosis and lordosis. *Spine* 7:335-342, 1982
 20. Stokes IAF: Biplanar radiography for measurement of spinal shape and motion. *Automedica* 6:37-49, 1985
 21. Stokes IAF, Bigalow LC, Moreland MS: Measurement of axial rotation of vertebrae in scoliosis. *Spine* 11:213-218, 1986