

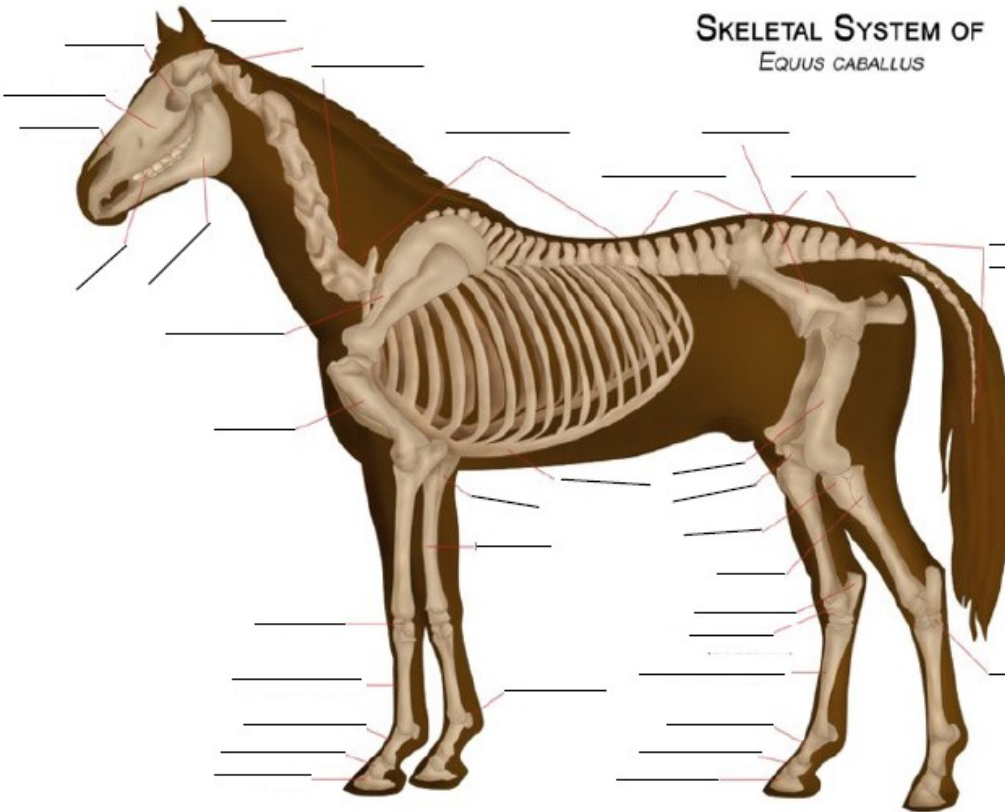


# 4-H Horse Activity #11



Fill in the blanks! Have fun!

**SKELETAL SYSTEM OF**  
EQUUS CABALLUS



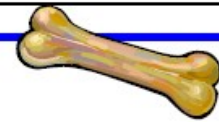
**Word Bank**

- Cranium
- Cervical Vertebrae (neck)
- Thoracic Vertebrae (chest)
- Lumbar Vertebrae (loin)
- Pelvis
- Sacral Vertebrae (pelvic)
- Coccygeal Vertebrae (tail)
- Tarsus
- Femur
- Patella (knee cap)
- Tibia
- Fibula
- Calcaneus (fibular tarsus)
- Talus (tibial tarsus bone)
- Metatarsal Bone (cannon)
- Metacarpal Bone (cannon)
- Long Pastern Bone
- Short Pastern Bone
- Coffin Bone
- Ribcage
- Ulna
- Radius
- Sesamoid Bones (fetlock)
- Carpus (knee)
- Humerous
- Scapula
- Teeth
- Mandible
- Nasal Bone
- Molar bone (cheek)
- Eye Socket

Try to think of the common names for the following skeletal parts:

Sacral Vertebrae: \_\_\_\_\_  
 Cervical Vertebrae: \_\_\_\_\_  
 Metacarpal Vertebrae: \_\_\_\_\_  
 Thoracic Vertebrae: \_\_\_\_\_  
 Coccygeal Vertebrae: \_\_\_\_\_

Mandible: \_\_\_\_\_  
 Carpus: \_\_\_\_\_  
 Patella: \_\_\_\_\_  
 Sesamoid bones: \_\_\_\_\_  
 Metatarsal (or metacarpal) bone: \_\_\_\_\_



*Created by Melinda Birch, April 2020*