

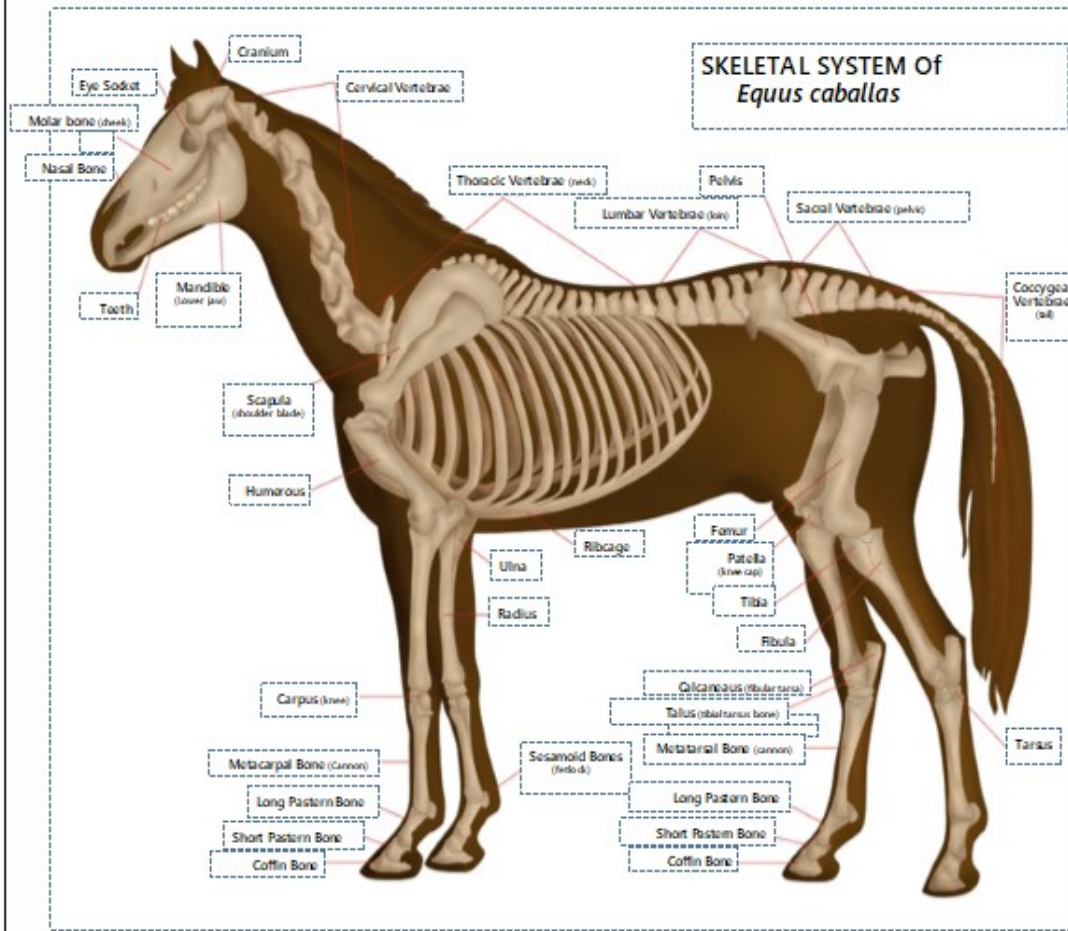


4-H Horse Activity #11

Answer Key



Fill in the blanks! Have fun!



Word Bank

- Cranium
- Cervical Vertebrae (neck)
- Thoracic Vertebrae (chest)
- Lumbar Vertebrae (loin)
- Pelvis
- Sacral Vertebrae (pelvic)
- Coccygeal Vertebrae (tail)
- Tarsus
- Femur
- Patella (knee cap)
- Tibia
- Fibula
- Calcaneus (fibular tarsus)
- Talus (tibial tarsus bone)
- Metatarsal Bone (cannon)
- Metacarpal Bone (cannon)
- Long Pastern Bone
- Short Pastern Bone
- Coffin Bone
- Ribcage
- Ulna
- Radius
- Sesamoid Bones (fetlock)
- Carpus (knee)
- Humerous
- Scapula
- Teeth
- Mandible
- Nasal Bone
- Molar bone (cheek)
- Eye Socket

Try to think of the common names for the following skeletal parts:

Sacral Vertebrae: _____ Rump _____
 Cervical Vertebrae: _____ Neck _____
 Metacarpal Vertebrae: _____ Cannon _____
 Thoracic Vertebrae: _____ Chest _____
 Coccygeal Vertebrae: _____ Tail _____

Mandible: _____ Jaw _____
 Carpus: _____ Knee _____
 Patella: _____ Knee cap _____
 Sesamoid bones: _____ Fetlock _____
 Lumbar Vertebrae: _____ Loin _____

